

## CASE REPORT

# Regenerative Potential of Platelet Rich Fibrin (PRF) Along With Bio-Gen® Putty in the Treatment of Periodontal Intrabony Defect— A Case Report

Sravani Gompa<sup>1</sup> Trinath Kishore D<sup>2</sup> K Raja V Murthy<sup>3</sup>

1. Corresponding author, Postgraduate student, Department of Periodontology and Oral implantology, GITAM Dental College and Hospital, Visakhapatnam.
2. Professor, Department of Periodontology and Oral implantology, GITAM Dental College and Hospital, Visakhapatnam.
3. Professor and Head of the Department of Periodontology and Oral implantology, GITAM Dental College and Hospital, Visakhapatnam.

## Abstract

*The need to increase the predictability of successful periodontal regeneration has led to the use of endogenous regenerative therapy in combination with osteoconductive scaffolds based on the principles of tissue engineering. The introduction of Choukroun's Platelet Rich Fibrin (PRF), has revolutionized the field of dentistry. PRF, a rich source of autologous growth factors and cytokines, is an upcoming therapeutic approach in the management of periodontal osseous defects. The present case report describes the treatment of an intrabony defect with platelet rich fibrin along with xenograft.*

**Key words:** Bio-Gen® putty, intrabony defect, periodontal regeneration, platelet rich fibrin

**Address for correspondence:** Dr. Sravani Gompa. Postgraduate student, Department of Periodontology and Oral implantology, GITAM Dental College and Hospital, Visakhapatnam. Ph.no 09246970097. Email: [drsraivilanka@yahoo.com](mailto:drsraivilanka@yahoo.com)

Received on :15/02/2016   Revised :16/02/2016   Accepted : 18/02/2016

## Introduction

Periodontal regeneration is defined as the complete replacement of lost periodontal structures, including formation of new cementum with new periodontal ligament (PDL) fibers, bone and gingiva.<sup>1</sup> Conventional open flap debridement offers only limited potential towards recovering the lost periodontal structures. Various grafting modalities have been used for periodontal tissue regeneration such as autogenous and allogenic bone grafts but none has been established as a gold standard in the treatment of intrabony defects, given their own associated limitations. Recently, attention

has shifted towards use of growth factors to regulate various cell-stromal interactions involved in periodontal regeneration. These growth factors are vital biologic mediators that can regulate the proliferation, chemotaxis and differentiation of the locally derived progenitor cells in the defect site.<sup>2</sup>

Platelets apart from their role in hemostasis have been reported to possess regenerative potential as their alpha granules are rich sources of various vital growth factors. They play a crucial role in periodontal regeneration as they are reservoirs of growth factors and cytokines which are the key factors for regeneration of the bone and maturation of the soft tissue.<sup>3</sup> Platelet

rich plasma (PRP) and platelet rich fibrin (PRF) are autologous platelet concentrates prepared from patient's own blood. The application of PRF in fields of plastic surgery, oral and maxillofacial surgery, periodontal therapy and implant surgery has demonstrated successful and rapid results in terms of bone regeneration.<sup>4</sup>

### **Materials used**

Bio-Gen® Putty: Fully enzyme deantigenised spongy bone and type I collagen powder, both of equine origin.<sup>4</sup> Platelet Rich Fibrin: PRF is a second generation platelet concentrate. It's completely autogenous in nature, with no artificial biochemical agents.<sup>5,6</sup>

### **Case Report**

A healthy 27 year old male patient has reported to the Department of Periodontics, GITAM Dental College and Hospital, with a chief complaint of food impaction since 1 year. Periodontal examination revealed periodontal pockets measuring 5mm in relation to 45 and 10 mm in relation to 46 [Fig.1]. Intra-oral periapical radiographs taken showed vertical bony defect in relation to 46 [Fig.7]. Probing Pocket depth (PPD) and Clinical attachment level (CAL) measurements were done using a Williams periodontal probe and University of North Carolina (UNC)-15 probe.

The treatment plan consisted of scaling and root planing followed by flap surgery with use of regenerative materials for the intrabony defect. The patient was advised 0.2 % chlorhexidine mouth rinse twice daily.

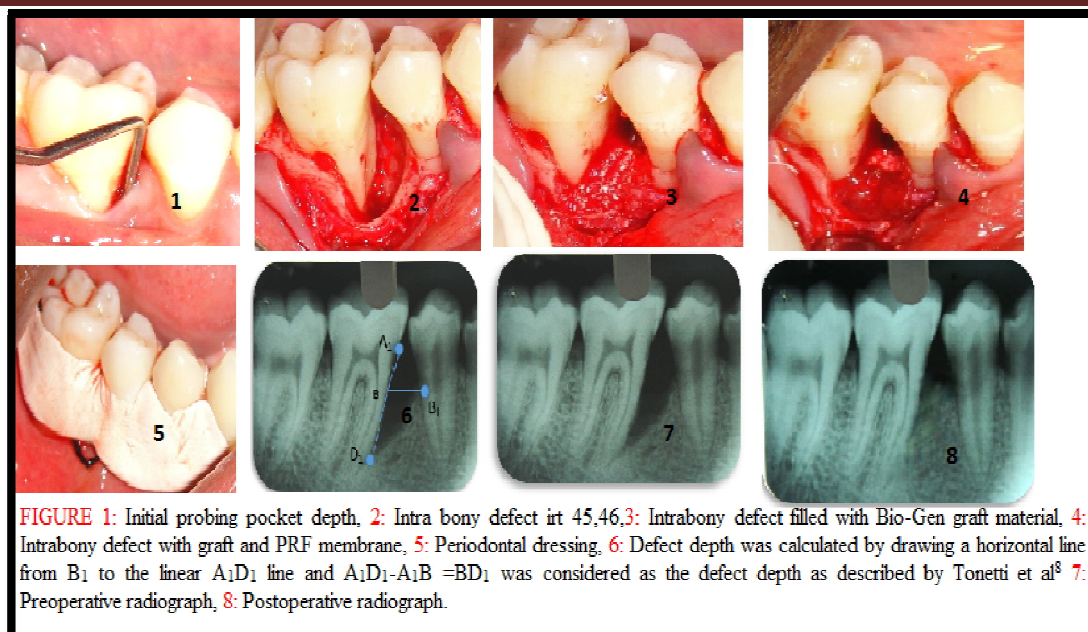
Patient was recalled 4 weeks after phase-I therapy and the clinical parameters were re-evaluated. Vitality test using electric pulp tester

revealed 46 as vital. Open flap debridement with regenerative therapy using a combination of platelet rich fibrin membrane, bone graft – “Bio-Gen® putty” was planned in relation to 45, 46 tooth region.

### **Surgical Phase**

After administration of local anesthesia, sulcular and interdental incision were given followed by elevation of full thickness flap in relation to 45, 46, 47. The area was debrided of subgingival calculus and granulation tissue and irrigated with normal saline. The intrabony defect [Fig.2] was filled with Bio-Gen® putty [Fig.3].

A venous blood sample was taken at the time of the surgery, and centrifuged according to the PRF protocol developed by Choukroun et al.<sup>5</sup> Briefly, 6 ml blood sample was taken from the patient without an anticoagulant in 10 ml glass test tubes and immediately centrifuged at 3000 rpm for 12 min. Superficial Platelet poor plasma was discarded, PRF was separated from red corpuscles base using sterile tweezers and scissors. The junction of PRF to RBC layer was preserved, as this region is supposed to be richest in all the growth factors.<sup>6,7</sup> The membrane was placed to cover the Bio-Gen® putty filling the intrabony defect [Fig.4]. This was followed by the approximation of facial and lingual flaps using simple interrupted sutures. The area was covered with non-eugenol periodontal dressing [Fig.5]. Post surgical instructions were given. The patient was prescribed Amoxicillin 500 mg, TDS for 5 days and Aceclofenac 100mg as needed. Chlorhexidine 0.2 % rinse thrice a day, was advised.



Following surgery, patient was re-evaluated at 6 and 9 months. Postoperative radiographic reviews after 9-month revealed a defect fill of approximately 60-70% [Fig.8]. Similarly, clinical examination at 9 months demonstrated a reduction in the PPD from 10mm (Pre-operative) to 5mm and CAL from 11 mm (Pre-operative) to 6 mm.

## Discussion

The most favourable outcome for periodontal therapy is to regenerate the lost supporting tissues. In the present case report, the patient was treated with PRF in combination with Bio-Gen® putty to attempt regeneration in intrabony defects in relation to 45, 46.

Platelet rich fibrin (PRF) described by Choukroun et al.<sup>5</sup> is a second generation platelet concentrate which contains platelets and growth factors in the form of fibrin membrane prepared from the patient's own blood. The PRF clot forms a strong natural fibrin matrix, which concentrates almost all the platelets and growth factors of the blood harvest. PRF enhances wound healing and regeneration and several studies have shown rapid and accelerated wound healing with the use of "PRF" than without it.<sup>6,7</sup>

Bio-Gen® putty is a Non-antigenic cancellous bone containing type I collagen obtained from equine source is commercially available as

nonimmunogenic, resorbable putty. It is deemed to be osteoconductive as well as osteoinductive in nature. The various advantages include its ability to act as a space maintainer, easy handling and its cost effectiveness. The only concern regarding Bio-Gen® putty is its nature of origin it is obtained from a donor of different species and may result in cross species antigenicity.<sup>4</sup> However, the histological evaluation by Sogal and Tofe et al confirmed good tolerance and good tissue acceptance of xenografts, with no risk of disease transmission.<sup>9</sup>

The three walled component of the defect (towards apex), provided the best spatial relationship for bridging of the graft materials with the vascular and cellular elements from the periodontal ligament and adjacent osseous wall. Also, space maintenance as provided by the defect walls helped to keep the PRF membrane in stable position thus providing protection and retention to the grafted material. Use of PRF as membrane to cover the apical two walled defect also appeared to be a successful adjunct to the maintenance of defect boundary as minimal recession and good bone fill was observed post-operatively.<sup>10</sup> Choukroun et al in his histological evaluation on effect of PRF on bone allograft in sinus lift procedure, reported a reduced healing time of 4 months with the addition of PRF. In

comparison, the histological maturation with FDBA alone was observed to be 8 months. This represents rapid healing and osteogenic ability of PRF.<sup>11</sup> The observations of present case report are in accordance with Choukroun's above mentioned study and the recently reported comparative studies involving the combination therapy of PRF with commercially available bone grafts.<sup>12</sup>

In the present report, a considerable reduction in PPD and CAL gain (5mm each) was observed 9 months post-operatively. Bone fill up to 60-70% was evident at 9 months with associated crestal bone formation, suggesting the arrest of disease activity. Thus results of the present report support the role of various growth factors present in the PRF in accelerating the soft and hard tissue healing. Radiographs revealed significant bone fill in the intrabony defect compared to measurements at baseline.

## Conclusion

Within the limitations of the study, it can be concluded that the combined use of Platelet rich fibrin and Bio-Gen® putty leads to significant improvements in clinical as well as radiographic parameters. Platelet rich fibrin, with its well established effects on hard- and soft-tissue cells, may thus have the potential to overcome the limitations of the conventional bone grafts and barrier membranes and promote periodontal regeneration.

**Conflict of Interest:** None declared

**Source of Support:** Nil

**Ethical Permission:** Obtained

## References

1. Lee J, Stavropoulos A, Susin C. Periodontal regeneration: Focus on growth factors and differentiation factors. *Dent Clin North Am* 2010;54:93-111
2. Chen FM, Sheton RM, Jin Y, Chapple IL. Localized delivery of growth factors for periodontal tissue regeneration: role, strategies, and perspectives. *Med res Rev* 2009;29:472-513
3. Ross R, Glomset J, Kariya B, Harker L. A platelet-dependent serum factor that stimulates the proliferation of arterial smooth muscle cells in vitro. *Proc Natl Acad Sci Usa* 1974;71:1207-1210
4. Santagata M, Guariniello L, D'Andrea A, Tartaro G. A modified crestal ridge expansion technique for immediate placement of implants: a report of three cases. *J Oral Implantol* 2008;34:319-324.
5. Dohan DM, Choukroun J, Diss A, et al. Platelet-rich fibrin (PRF): A second-generation platelet concentrate. Part II: Platelet-related biologic features. *Oral Surg Oral Med Oral Pathol Oral Radiol Endod.* 2006 b;101:e45-e50.
6. Dohan DM, Choukroun J, Diss A, Dohan SL, Dohan AJ, Mouhyi J, Gogly B. Platelet-rich fibrin (PRF): a second-generation platelet concentrate. Part III: leucocyte activation: a new feature for platelet concentrates? *Oral Surg Oral Med Oral Pathol Oral Radiol Endod* 2006c;101:e51-e55.
7. Dohan DM, Choukroun J, Diss A, Dohan SL, Dohan AJ, Mouhyi J, Gogly B. Platelet-rich fibrin (PRF): A second-generation platelet concentrate. Part I: Technological concepts and evolution. *Oral Surg Oral Med Oral Pathol Oral Radiol Endod.* 2006a;101:e37-e44
8. Tonetti MS, Pini-Prato G, Cortellini P. Periodontal regeneration of human intrabony defects: IV: Determinants of healing response. *J Periodontol* 1993;64:934-940
9. Sogal A, Tofe AJ. Risk assessment of bovine spongiform encephalopathy transmission through bone graft material derived from bovine bone used for dental applications. *J Periodontol* 1999 ;70:1053-1063
10. Blumenthal NM, Mario EAF, Salah A, Al-Huwais, Hofbauer AM, Koperski RD. Defect-Determined Regenerative Options for Treating Periodontal Intrabony Defects in Baboons. *J Periodontol* 2003;74:10-24
11. Choukroun J, Diss A, Simonpieri A, Girard MO, Schoeffler C, Dohan SL, Dohan AJ, Mouhyi J, Dohan DM. Platelet-rich fibrin (PRF): a second-generation platelet concentrate. Part V: histologic evaluations of PRF effects on; bone allograft maturation in sinus lift. *Oral Surg Oral Med Oral Pathol Oral Radiol Endod* 2006 b;101:299-303.
12. Lekovic V, Camargo P M, Weinlaender M, Vasilic N. Comparison of platelet rich plasma and bovine porous bone mineral in the treatment of intrabony defects: a re-entry study. *J Periodontol* 2002;73:198-205.