

## ORIGINAL ARTICLE

# Pap smear analysis of HIV Positive Rural Females of West Godavari District of Andhra Pradesh India

Sridhar Reddy R<sup>1</sup>, Sunitha K<sup>2</sup>, Ravi Surada<sup>3</sup>

Assistant Professor of Pathology<sup>1</sup>, Statistician, Department of Community Medicine<sup>3</sup>, RIMS Adilabad  
Pathologist Jangareddygudem West Godavari District<sup>2</sup>

<http://dx.doi.org/10.18049/jcmad/215>

## Abstract

*Cervical cancer is the second most common cancer in the women of developing countries. Nearly half of 8 million persons infected with HIV are women, in them Cervical cancer is the most common AIDS related malignancy. HIV infected women have high incidence and persistence rates of HPV and SIL. In the regional population of West Godavari district of Andhra Pradesh India women with HIV are at higher risk for SIL and candidiasis and degree of immunosuppression correlates with SIL. ART has a role in reducing the opportunistic infections, but has limited role on the progression of SIL. Implementation of Pap screening in rural hospitals can help HIV positive people to lead productive life. Early detection of precancerous lesions by Pap smears will be useful for prevention of progression of the lesions.*

**Key words:** HIV, HPV, SIL

**Address for correspondence:** Dr. Sridhar Reddy R, Department of Pathology, RIMS Adilabad, A.P. India. Email: [rdd.sridhar@gmail.com](mailto:rdd.sridhar@gmail.com)

## Introduction

Cervical cancer is one of the most common cancers prevalent in females of low socioeconomic or developing countries.<sup>1</sup> Its rank is 10<sup>th</sup> among all cancers which occur in both male and females globally and it is the second most common cancer among females after breast cancer worldwide.<sup>2</sup> Precancerous lesions are more common in HIV positive females in comparison of HIV negative females as progression rate; incidence and prevalence of such lesions are higher in HIV positive females.<sup>3</sup> Nearly half of 8 million persons infected with HIV are women, in them Cervical cancer is the most common AIDS related malignancy. HIV infected women have high incidence and persistence rates of Human Papilloma Virus (HPV) and Squamous Intra Epithelial Lesions (SIL- Abnormal epithelial lesions). Hence the present study was conducted to determine the incidence of SIL in HIV positive women and to determine the incidence of opportunistic infections in HIV positive women by screening methods like Papanicolaou (Pap) smear analysis of cervical lesions which can be useful for the

reduction of cervical burden in HIV positive cases.<sup>4</sup> Moreover, the study was conducted in West Godavari District of A.P. Pradesh, India with the intention of collection of regional data.

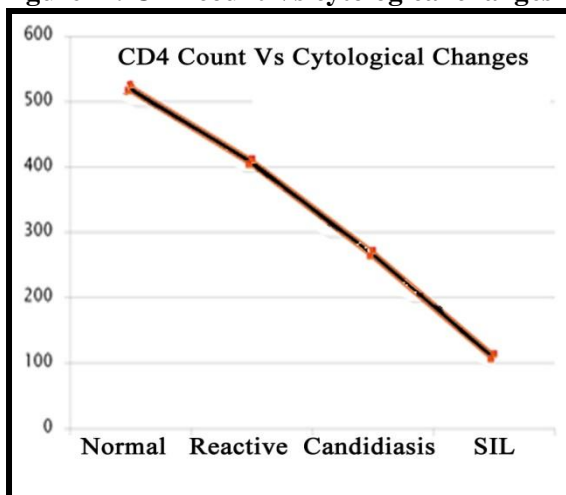
## Materials and Methods

It was a cross sectional study which was carried out between during July - September 2010 in 3 primary health centers of West Godavari District of Andhra Pradesh India. All the females were from surrounding rural regions of the centres. Hospital based Pap screening camps were conducted. A total of 50 HIV positive and 50 HIV negative cases were enrolled after taking informed consent. The spatula was used for smear collection. Cervical smears immediately fixed in alcohol and stained with Pap. Slides were evaluated by the pathologist by using light microscopy and the modified Pap method. Pap smear results were rated according to 2001 Bethesda classification.<sup>5</sup> The other criteria were age at marriage, HIV diagnosed date, CD4 count and Anti retroviral therapy (ART) status.

## Results

Most of the HIV positive cases (24 numbers) were in between the age group of 21-30 years followed by age group of 31-40 years (18 cases) and 16-20 years (8 cases) table -1). Cytological changes in cervical smears revealed inflammatory changes in 46 smears followed by 33 within normal limit (Table -2). 21 (48%) HIV positive cases showed reactive changes while these changes were more in non HIV cases (25 cases, 52%). 15(34%) HIV positive cases showed within normal limit while within normal limit was observed in 18 (37%) non HIV cases (Table -3). When cervical smears compared between patients on antiretroviral therapy (ART) and non ART, inflammatory changes were observed in 9 patients who were on ART while it was seen in 13 non ART cases. 8 cases on ART showed within normal limit while only 5 cases on non ART showed it (Table -3). SIL (5 cases) was mostly associated with HIV positive cases while it was one in case of HIV negative cases. Other lesions were more common in HIV negative cases (47 cases) in comparison to HIV positive cases (39 cases). With decrease in CD4 count in HIV positive cases various changes were observed like reactive changes at around 400 CD4 count followed by candidiasis (CD4 count around 300) and SIL (CD4 count around 100 (Fig.-1).

**Figure -1: CD4 count Vs cytological changes**



**Table -1: Age wise distribution (n=100)**

Age (Years)	HIV +ve	HIV -ve	Total
16-20	08(16%)	17(34%)	25(50%)
21-30	24(48%)	21(42%)	45(90%)
31-40	18(36%)	10(20%)	28(56%)
>40	0(00%)	2(04%)	02(04%)
<b>Total</b>	<b>50</b>	<b>50</b>	<b>100</b>

**Table -2: Cytological changes**

Changes	No.	Percentage
Inadequate	8	16
Within normal limits	33	66
Inflammatory smears	46	92
Infections	04	08
Candidiasis	03	06
SIL*	06	12

\*Abnormal Squamous epithelial lesions (SIL)

**Table -3: Comparison of Cytological changes**

Total cases 100	HIV Positive (N=44)	HIV Negative (N=48)
Within normal limits	15(34%)	18(37%)
Reactive changes	21(48%)	25(52%)
Infectious changes	0(00%)	04(9%)
Candidiasis	03(7%)	0(00%)
LSIL*	04(9%)	01(2%)
HSIL*	02(2%)	0(00%)

\*Low-grade intraepithelial lesion (LSIL)

\*High-grade intraepithelial lesion (HSIL)

**Table -4: Comparison of cervical smears**

Cervical smears	On ART	Non ART
Within normal limit	08	05
Inflammatory changes	09	13
Candidiasis	Nil	03
SIL	05	01

## Discussion

To obtain data about prevalence of status of precancerous lesions in the regional population of HIV positive females, present study was conducted so that the exact scenario can be assessed which will be useful for better policy initiation for the management of the HIV positive females. We document that the prevalence of precancerous lesions is high in

these women in comparison to HIV negative females. In the present study we found 11% abnormal epithelial lesions (SIL) including 9% low-grade squamous intraepithelial lesion (LSIL) and 2% high-grade squamous intraepithelial lesion (HSIL) in HIV positive cases while total SIL was only 2% in non HIV cases with only 2% LSIL.

Moodley et al<sup>6</sup> in 2004 at Western Cape Town found 23% total SIL with 14% LSIL and 9% HSIL in HIV positive cases while in HIV negative total SIL was 6% with 3% each SIL and HSIL. Rocha-Brischiliari SC et al<sup>7</sup> in 2014 at Brazilian HIV infected females found high frequency of HPV infection (46.6%) but with a low frequency of cervical abnormalities (7.30%), mainly low-grade squamous intraepithelial cervical lesions (LSIL) (84.6%). A high frequency of multiple HPV infections was also detected (23.0%). Prevalence of highest number of SIL was observed in HIV positive females living in Zambia as the prevalence of SIL (76%) was detected in a study of 150 HIV-positive women in Zambia who had a median CD4 count of 165/uL.<sup>8</sup> Lowest number of SIL (7%) prevalence was reported in a study of 691 HIV positive females which was conducted in Tanzania. Most of the HIV positive females (86%) in the study were in WHO clinical stage I category and only 12% of the them were having CD4 count less than 200.<sup>9</sup> In the present study HIV positive females with lower CD4 counts (around 100) were prone for SIL and thus appeared more likely to have severe lesions indicating low CD4 count, high HIV viral load and or infection with high-risk HPV types are associated with the presence of SIL. Yamada R et al<sup>10</sup> in Nairobi, Kenya, Leroy V et al<sup>11</sup> in Kigali, Rwanda and Parham GP et al<sup>8</sup> in Lusaka, Zambia also observed greater association of SIL with Human Papilloma Virus and low CD4 count.

Comparatively with other studies we found less total number of SIL incidences but our finding is similar to other mentioned studies in which they found higher number of SIL in HIV positive females in comparison to HIV negative females. The prevalence of SIL in the present study might be influenced by population characteristics or the accuracy of cytology

results. Although three different primary health centers of rural regions were selected but the samples may not have been exactly representative of all HIV-positive women in entire Andhra Pradesh state of India as those centers were conveniently selected and not randomly chosen. Still we do not expect much difference in the rural region of West Godavari District of state of Andhra Pradesh as the primary health centers sampled have good number of HIV positive patients.

The relatively low prevalence of cervical lesions in the studied population indicates that even Pap smear offer a screening tool for cervical precancerous lesions in HIV-positive women. Previously these females were not screened for precancerous lesions although such females have higher risk of cervical cancers. Antiretroviral drugs (ART) are sufficiently available free of cost in the region which indicates that we can expect increased survival of HIV positive females. But it does not rule out the need of screening for precancerous lesion for cervical cancers as number of SIL is more in the present study in HIV positive cases on ART in comparison to non ART HIV positive cases. Hence even patients are on antiretroviral drugs still there is a need of screening for precancerous lesion for cervical cancers in the region is needed. Gaym A et al<sup>12</sup> also indicated the need of precancerous screening for cervical cancer in HIV positive females for better management of HIV population.

## **Conclusion**

We conclude that women with HIV are at higher risk for SIL and candidiasis and degree of immunosuppression correlates with SIL. ART has a role in reducing the opportunistic infections, but has limited role on the progression of SIL. Implementation of Pap screening in rural hospitals can help HIV positive people to lead productive life. Early detection of precancerous lesions by Pap smears will be useful for prevention of progression of the lesions. But still our opinion is that there is a need of a prospective study with sufficiently larger sample size for better understanding of the problem.

**Source(s) of support:** Nil

**Conflict of Interest:** None declared

## References

1. WHO. Preparing for the introduction of HPV vaccines: policy and programme guidance for countries. WHO; Geneva: 2006.
2. Parkin DM, Bray F, Feslay J, Pisani P. Estimating the world cancer burden: Globocan 2000. *Int J Cancer*. 2001;94:153–6.
3. De Vuyst H, Lillo F, Broutet N, Smith JS. HIV, human papillomavirus, and cervical neoplasia and cancer in the era of highly active antiretroviral therapy. *Eur J Cancer Prev*. 2008;17(6):545–54.
4. Franceschi S, Jaffe H. Cervical cancer screening of women living with HIV infection: a must in the era of antiretroviral therapy. *Clin Infect Dis*. 2007;45(4):510–3.
5. Solomon D, Davey D, Kurman R, Moriarty A, O'Connor D, Prey M, et al. The 2001 Bethesda System: terminology for reporting results of cervical cytology. *JAMA*. 2002;287(16):2114–9.
6. Moodley M, Garib R. The significance of human papillomavirus infection detected by cervical cytology among women infected with the human immunodeficiency virus. *J Obstet Gynaecol*. 2004;24(8):903–6.
7. Rocha-Brischiliari SC, Gimenes F, de Abreu AL, Irie MM, Souza RP, Santana RG, Gravena AA, de Carvalho MD, Consolaro ME, Pelloso SM. Risk factors for cervical HPV infection and genotypes distribution in HIV-infected South Brazilian women. *Infect Agent Cancer* 2014;9(1):6.
8. Parham GP, Sahasrabudde VV, Mwanahamuntu MH, Shepherd BE, Hicks ML, Stringer EM, et al. Prevalence and predictors of squamous intraepithelial lesions of the cervix in HIV-infected women in Lusaka, Zambia. *Gynecol Oncol*. 2006;103(3):1017–22.
9. Kapiga SH, Msamanga GI, Spiegelman D, Mwakyoma H, Fawzi WW, Hunter DJ. Risk factors for cervical squamous intraepithelial lesions among HIV-1 seropositive women in Dar es Salaam, Tanzania. *Int J Gynaecol Obstet*. 1999;67(2):87–94.
10. Yamada R, Sasagawa T, Kirumbi LW, Kingoro A, Karanja DK, Kiptoo M, et al. Human papillomavirus infection and cervical abnormalities in Nairobi, Kenya, an area with a high prevalence of human immunodeficiency virus infection. *J Med Virol*. 2008;80(5):847–55.
11. Leroy V, Ladner J, De Clercq A, Meheus A, Nyiraziraje M, Karita E, et al. Cervical dysplasia and HIV type 1 infection in African pregnant women: a cross sectional study, Kigali, Rwanda. The Pregnancy and HIV Study Group (EGE) Sex Transm Infect. 1999;75(2):103–6.
12. Gaym A, Mashego M, Kharsany AB, Walldorf J, Frohlich J, Karim QA. High prevalence of abnormal Pap smears among young women co-infected with HIV in rural South Africa - implications for cervical cancer screening policies in high HIV prevalence populations. *S Afr Med J* 2007;97(2):120–3.