

CASE REPORT

Carcinosarcoma – Rare Presentation

Sridhar Reddy R¹, Ramalakshmi PVB²

Assistant Professor of Pathology, RIMS Adilabad¹, Professor & Head of Pathology, MIMS Vijayanagram² A.P. India.
<http://dx.doi.org/10.18049/jcmad/218>

Abstract

Carcinosarcoma is a rare biphasic neoplasm, with distinct malignant epithelial and mesenchymal components. Most of the patients with carcinosarcoma are elderly males. It has aggressive malignant potential with poor prognosis. Here we present unusual case of Carcinosarcoma (Primary/Metastatic) arising in 45 years old male and presented as large localized mass in the left loin region. Distinction from whether it is primary or secondary could not be done because patient did not turn up even for the report.

Key words: Carcinosarcoma, Biphasic neoplasm, Localized mass

Address for correspondence: Dr. Sridhar Reddy R, Department of Pathology, RIMS Adilabad, A.P. India. Email: rdd.sridhar@gmail.com

Introduction

Carcinosarcomas are rare malignant and aggressive tumors that can arise anywhere in the body, especially in the genitourinary system. They are seen most often in the bladder in men, and uterus in women in the. They usually present in patients age 60 years and above, and are more common in men than women. The exact histogenesis of carcinosarcomas remains unknown and is debated in the literature. Histologically, most of these tumors are high grade, and the prognosis is poor.⁽¹⁾ Metastases develop in regional lymph nodes and distantly. Carcinosarcomas presenting as large localized palpable mass (whether Primary/Secondary) in left loin region is very rare presentation.

Case Report

45 years old male presented with a growth in the left loin region, with gradual increase in size. No other complaints. The swelling was not fixed to the underlying structures and was excised outside in local hospital and sent to pathology department of ASRAM Medical College, Eluru. Grossly the skin covered soft tissue mass was measuring 6x4x3 cms, externally nodular with discoloration on the surface. Cut section shows

grey white and Grey brown areas (Figure-1A&B). Microscopically the lesion was covered by stratified squamous epithelium and composed of two components abutting each other. The epithelial component (Figure-2) constitutes of cells arranged predominantly in acinar pattern and few in nests and sheets. The epithelial cells are pleomorphic with moderate amount of cytoplasm, prominent nucleoli and in few sheets there was vacuolated cytoplasm. The spindle cell component was with highly pleomorphic cells with irregular nuclear chromatin and prominent nucleoli and high mitotic activity. There were osteosarcoma like areas and osteoclast like giant cells. Areas of necrosis and haemorrhage along with perivascular arrangement of the tumor cells were seen occasionally. With these morphological features the differential diagnoses considered were Biphasic Synovial Sarcoma, Biphasic Mesothelioma, Carcinosarcoma, Extraskelatal Osteosarcoma and Glandular MPNST.

In case of Biphasic Synovial Sarcoma, when it arises in unusual sites other D/D are also to be considered. Mass is usually associated with pain and tenderness, usually deeply located. Atypical features of both components are of lesser degree. In case of Biphasic Mesothelioma, it occurs in pleura, pericardium, peritoneal cavity and scrotum. Usually gradual transition between spindle and epithelial areas is seen. In Glandular

MPNST, presence of intestinal epithelium with goblet cells is seen. While in case of Extra

Skeletal Osteosarcoma, no epithelial elements are seen.

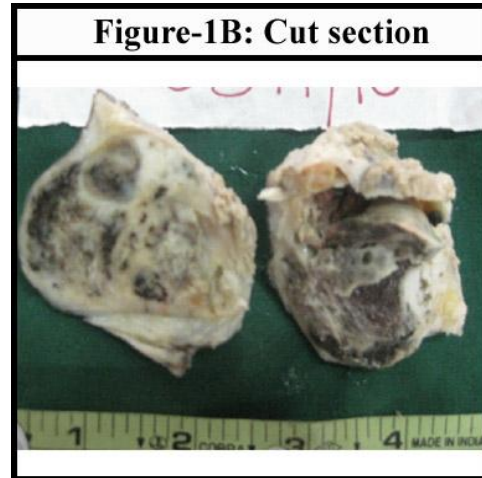
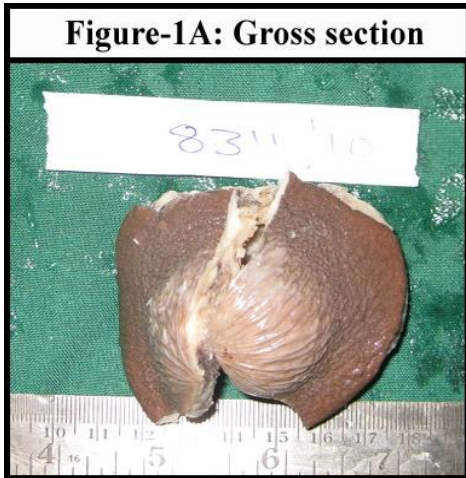

Figure-2: Malignant epithelial component mostly forming acinar pattern, sheets, cords

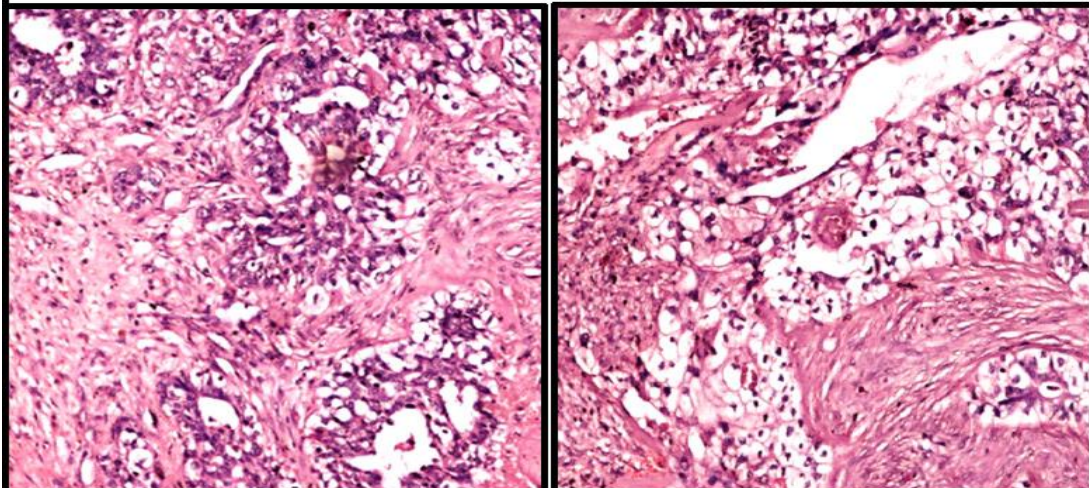
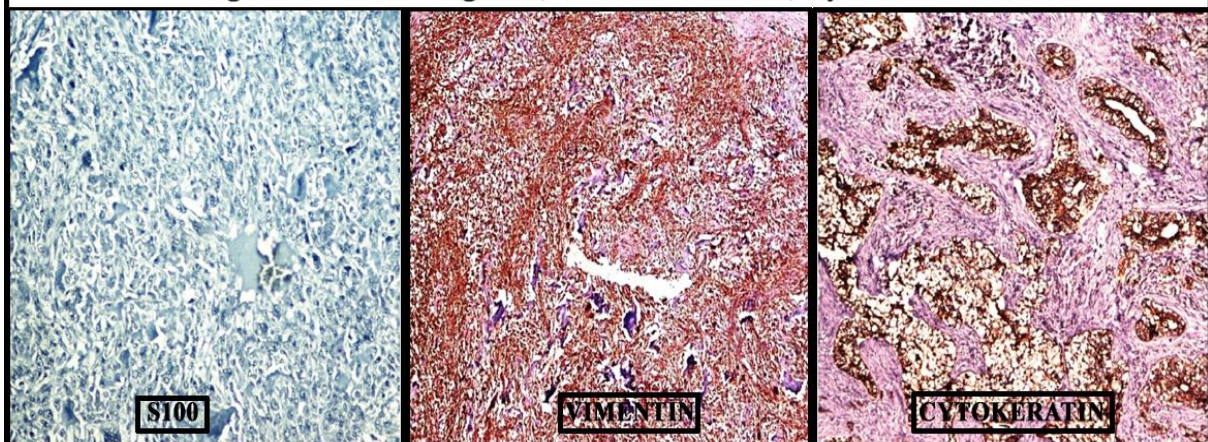


Figure- 3: S100- Negative, Vimentin Positive, Cytokeratin Positive



With these differential diagnoses, IHC was done for the markers. S100- negative,

Carcinomatous component showed CYTOKERATIN & EMA positivity and

Sarcomatous component showed VIMENTIN positivity (Figure-3). Final diagnosis of Carcinosarcoma was confirmed. The patient did not even turn to take the report and we could not trace out the patient since the specimen is sent from a local rural hospital and therefore could not rule out the renal/bladder status hence the tumor whether from primary or metastatic deposit cannot be commented. In spite of that Carcinosarcoma occurring at 45 years as localized single palpable mass is unusual and rare presentation.

Discussion & Conclusion

Carcinosarcoma is a rare biphasic neoplasm, with distinct malignant epithelial and mesenchymal components. A true Carcinosarcoma is a biphasic tumor with distinct carcinomatous and sarcomatous elements, believed to be derived from a common stem cell;⁽²⁾ however, the exact histogenesis of these tumors has not been elucidated.⁽³⁾

Carcinosarcoma is high grade neoplasm in which a malignant epithelial component, clearly identifiable as such (of transitional, glandular, squamous or undifferentiated type), coexists with sarcoma like appearance. The latter may have nonspecific spindle cell or pleomorphic look, sometimes admixed with osteoclast like giant cells. It may exhibit specific features of mesenchymal differentiation such as rhabdomyosarcoma, chondrosarcoma, osteosarcoma, liposarcoma or malignant fibrous histiocytoma.

Most of the patients with carcinosarcoma are elderly males and death rate is about 50%. Metastases develop in regional lymph nodes and distantly, they may consist of only epithelial or the sarcoma like component.⁽²⁾ In our case 45 years male presented with localized palpable mass in left loin and no other complaints. Our case has both the epithelial and sarcomatous components with severe atypical features.

Ram et al reported a primary cutaneous carcinosarcoma.⁽⁴⁾ Ishimura et al reported synchronous multiple carcinosarcoma of the renal pelvis and ureter.⁽⁵⁾ Yoshida et al reported a case of carcinosarcoma originating from renal

pelvis.⁽⁶⁾ A case of carcinosarcoma presenting as large localized mass (primary/metastatic) is very rare presentation, the primary could not be evaluated. Carcinosarcomas occur in various organs, but with the correlation of site (loin region), metastatic deposit from renal/bladder can be considered. Carcinosarcoma has an aggressive malignant potential and poor prognosis.⁽²⁾ Surgical treatment is the primary treatment of choice. Adjuvant radiotherapy or chemotherapy has not been shown to significantly improve prognosis.⁽⁷⁾

Source(s) of support: Nil

Conflict of Interest: None declared

References

1. Perimenis P, Athanasopoulos A, Geraghty J, Speakman M. Carcinosarcoma of the ureter: a rare, pleomorphic, aggressive malignancy. *Int Urol Nephrol* 2003;35:491-3.
2. Halachmi S, DeMarzo AM, Chow NH et al. Genetic alterations in urinary bladder carcinosarcoma: evidence of a common clonal origin. *Eur Urol* 2000;37:350-7.
3. Angela Darko, Kasturi Das, Rahul Dev S Bhalla, Debra Heller. Carcinosarcoma of the ureter: Report of a case with unusual histology and review of the literature. *Int J Urol* 2006;13(12):1528-31.
4. Ram R, Saadat P, Peng D, Vadmal M. Primary cutaneous carcinosarcoma. *Ann Clin Lab Sci* 2005;35(2):189-94.
5. Yoshida T, Ogawa T, Fujinaga T, Kusuyama Y. A case of carcinosarcoma originating from the renal pelvis. *Nihon Hinyokika Gakkai Zasshi* 1990;81(11):1739-42.
6. Ishimura H, Momose A, Narita S, Kurotaki H. Synchronous multiple carcinosarcoma of the renal pelvis and ureter: A case report. *Hinyokika Kyo* 2010;56(7):381-4.
7. Perimenis P, Athanasopoulos A, Geraghty J, Speakman M. Carcinosarcoma of the ureter: a rare, pleomorphic, aggressive malignancy. *Int Urol Nephrol* 2003;35:491-3.