

## CASE REPORT

# Adult Filarial Worms in tissue sections of a painless Breast Mass

Veena Kumari L<sup>1</sup>, Sridhar Reddy R<sup>2</sup>

Professor and HOD of Pathology<sup>1</sup>, Assistant Professor<sup>2</sup> of Pathology, RIMS Adilabad, A.P. India.  
<http://dx.doi.org/10.18049/jcmad/219a10>

## Abstract

Filariasis is a global health problem. Lymphatic Filariasis caused by *Wuchereria bancrofti* and *Brugia malayi*, it is an important public health problem in India. Both parasites produce pathology limited to lymphatic system and are essentially has similar clinical presentations in humans. Presence of microfilaria & adult worm in breast lump histopathological sections is a rare finding. We report an unusual case of filarial worm with surrounding granulomatous inflammation in breast mass of a 35yrs old woman who presented with a painless lump in breast since 2 months. It was diagnosed clinically as Fibroadenoma. FNAC showed mainly chronic inflammatory cells was inconclusive. The mass was excised & processed for histopathological examination which confirms the presence of adult filarial worm with surrounding granuloma in breast mass.

**Key words:** Adult Filarial Worm, Breast Mass, Granuloma

**Address for correspondence:** Dr. Veena Kumar L, Department of Pathology, RIMS Adilabad, A.P. India. Email: [rdd.sridhar@gmail.com](mailto:rdd.sridhar@gmail.com)

## Case Report

### Introduction

Filariasis is a serious global socioeconomic & public health problem. Lymphatic Filariasis (LF) is a major cause of acute and chronic morbidity in humans in 73 countries in Asia, Africa, the Western Pacific and the Americas. Nearly 1.4 billion people are exposed to infection from mosquito-borne filarial parasites (*Wuchereria bancrofti* and *Brugia malayi*)<sup>[1]</sup>. Filariasis is common in coastal areas of India – the endemic areas are mainly the sea coast & banks of large rivers in 17 States and six Union Territories, with about 553 million people at risk of infection<sup>[2]</sup>. The disease mainly involves the lymphatic system of the body. Although the incidence is high in Indian subcontinent, yet it is unusual to find microfilaria & adult worms in breast mass & only few such cases have been documented<sup>[3,4]</sup>. In lymphatic filariasis the sites commonly involved are lungs, bronchial aspirates, cervicovaginal smears, pleural & pericardial fluids<sup>[5-8]</sup>.

A 35 yrs old female presented with a slow growing painless mass on outer quadrant of left breast duration of 2 months. Clinical examination revealed a mobile mass measuring 3/2/2 cms. Not fixed to skin, the nipple and areola or underlying structures and no axillary lymphadenopathy. Systemic examination revealed no significant abnormal findings. Routine hematological investigations were normal. Peripheral blood smear examination failed to reveal eosinophilia or presence of any hemoparasites. Clinically it was diagnosed as fibroadenoma breast. FNAC of the breast mass revealed only chronic inflammatory cells and was inconclusive. The mass was excised in toto & send for histopathological examination.

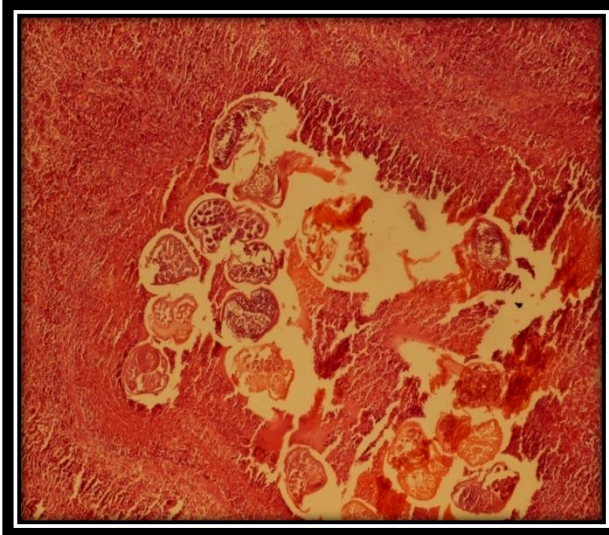
**Grossly:** the excised specimen was soft tissue mass with adhering fatty tissue measures 3/2/2 cms. Cut section is greyish white.

**Microscopic** sections of the mass revealed center of the lesion showed an adult microfilarial worm (slide 1). The worm was cut in several planes surrounded by sheets of chronic inflammatory cells composed of predominantly lymphocytes, occasional plasma

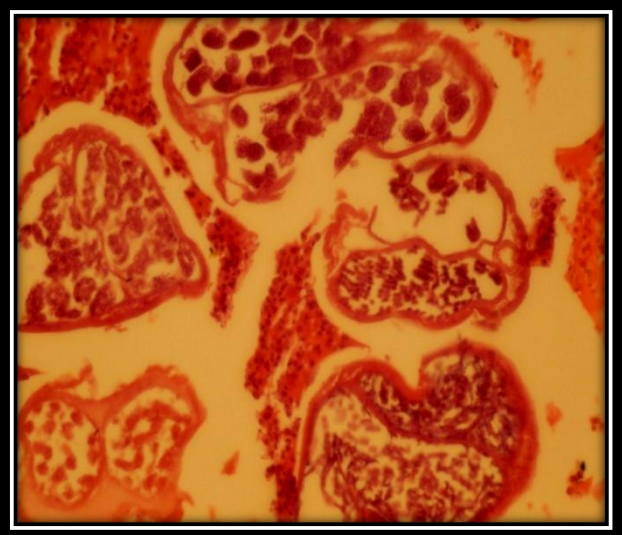
cells & histiocytes. Cut section of this worm showed paired tubular structures containing

small round bodies (uterus) and an empty tubular structure (intestine). Surrounding tissue showed fibroblasts and adipocytes.

**Slide -1: Microfilariae H & E stain low Power**



**Slide -2: High power magnification of the stain**



## Discussion

Usually the term “Filariasis” refers to Lymphatic Filariasis [LF] caused by two closely related nematode worms – *Wuchereria Bancrofti* & *Brugia Malayi*. These parasites have biphasic life cycles involving humans and various species of mosquito vectors from the genera *Anopheles*, *Aedes*, *Culex*, *Mansonia* and *Ochlerotatus* [9]. *Culex* mosquitoes are the principal vectors of LF in Asia [1]. Adult worms are found in the lymphatic vessels and lymph nodes of human beings only. Filariasis is a global health problem of huge magnitude. It is endemic in large areas of India especially in coastal areas. As on 2006 December the total population at risk of lymphatic filariasis was estimated to be 1254 million in 83 endemic countries of which 64% was contributed by South East Asia region (SEAR) alone [10]. In India it is estimated that 554.2 million populations were at risk of lymphatic filariasis infection [10]. Adult worm lives in the lymphatic system of definitive host microfilariae is released and circulated in the peripheral blood causing lymphaginitis, lymphadenitis and lymphedema resulting in elephantiasis are its

various manifestations [11]. Diagnosis is made by these tests:

- 1) Demonstration of microfilaria in peripheral smears of blood or skin which have nocturnal periodicity in most parts of the world.
- 2) detection of filarial antigen & antibody by very sensitive, very specific simple “card test” using only finger prick blood droplets taken anytime of the day very useful now.
- 3) Adult worms can be detected in lymphatics or scrotum in affected person.

Female breast is an unusual site for the occurrence of filarial granuloma and only few such cases have been documented in literature [3, 4]. It is frequently caused by *W.bancrofti*. The patients usually present with solitary, nontender, unilateral breast mass. Multiple lesions are uncommon. The upper & outer quadrant is the most common site. But central or periareolar nodules occur with notable frequency. Most of the lesions may involve subcutaneous tissue & present as a hard mass with cutaneous attachment and clinically mistaken for carcinoma. The diagnosis of filarial granuloma of breast was made depending on the specific microscopic structural features of the adult worm. In the present case microfilaria were not demonstrable in night blood smears. Only

histopathological examination confirmed the presence of adult worm with prominent granulomatous inflammation around it. As the patient did not have any clinical evidence of filariasis & there was no microfilaraemia, the patient had occult filariasis. This can be seen in endemic areas where filariasis can exist without microfilaraemia or it may be extremely transient & hence overlooked. Fine needle aspiration yielded mostly chronic inflammatory cells and reported as inflammatory.

### Conclusion

Filarial granuloma in the breast although an unusual presentation in India, but it is usually commonly seen in some endemic areas like China & Srilanka. This case shows that presence of filarial granuloma in breast mass may be a possibility in countries like India. All unexplained granulomas in breast should include filarial granuloma in differential diagnosis especially in endemic areas like India. This case also demonstrates that FNAC may be helpful in diagnosis of microfilariae but some times may remain inconclusive to detect the parasite as in our case. Complete histopathological examinations may be necessary to confirm the presence of adult parasites.

---

**Source(s) of support:** Nil

**Conflict of Interest:** None declared

---

### References

1. WHO (2013) Lymphatic Filariasis. Fact sheet No 102. Available:

- <http://www.who.int/mediacentre/factsheets/fs102/en/>. Accessed Dec 30, 2013.
2. Raju K, Jambulingam P, Sabesan S, Vanamail P. Lymphatic filariasis in India: epidemiology and control measures J Postgrad Med. 2010 Jul-Sep;56(3):232-8.
  3. Chandrasoma PT, Mendis KN Filarial infection of the breast.. Am.Jr. of Tropical medicine & Hygeine.1978; 27:770-773.
  4. Yuechan C, Qunx Filarial granuloma of the female breast.a histopathological study of 131 cases Am.Jr. of Tropical medicine & Hygeine1981,30,1206-10.
  5. Konar A. Microfilaria in lung - diagnosis by FNAC. Ind J Pathol Microbiol 2003; 46:279-80.
  6. Anupindi L, Sahoo R, Rao RV, Varghese G, Rao PVP. Microfilariae in bronchial brushing cytology of symptomatic pulmonary lesions - a report of two cases. Acta Cytol 1993; 37:397-99.
  7. ValandAG, Ramraje SN, Surase S. Microfilaria of Wuchereria bancrofti in cervicovaginal smear. Ind J Pathol Microbiol 2004; 47:597-98.
  8. SamantaraySK, PulimoodBM. Filarial pericardial effusion. J Assoc Physician India 1975; 23: 349-51
  9. Sebastian S sandip kumar *et al*; Seasonal abundance and biting behavior of mansonina annulifera, mansonina uniformis and mansonina Indiana and their relative role in the transmission of Malayan filariasis in shertallai (Kerala State). Indian J med Res 93:253:1992.
  10. Weekly epidemiological record Geneva World health Organization 2007; 82(42): 361-80.
  11. Park K Text Book of Preventive and social Med 21<sup>st</sup> Edition Jabalpur Banarasidas Bhanot Publishers:2011 epidemiology of communicable diseases pp 244-50.