

## CASE REPORT

### Early Ossification of Anterior Longitudinal Ligament: A Case Report

[Tambe SV](#)<sup>1</sup>, [Golghate TD](#)<sup>2</sup>, [Rahule AS](#)<sup>3</sup>, [Meshram MM](#)<sup>4</sup>, [Kasote AP](#)<sup>3</sup>, [Kamdi NY](#)<sup>3</sup>, [Thakre BP](#)<sup>1</sup>

Assistant Professor<sup>1</sup>, Professor<sup>2</sup>, Associate Professor<sup>3</sup>, Professor & Head<sup>4</sup>  
Department of Anatomy, Government Medical College, Nagpur, MS, India.

<http://dx.doi.org/10.18049/jcmad/229a15>

#### Abstract

Ossification of the anterior longitudinal ligament (OALL) has not been widely described since it is rarely symptomatic. The ossification and or calcification of the spinal ligaments have been considered as a part of diffuse idiopathic skeletal hyperostosis, previously known as Forestier's disease. It is defined as a diffuse idiopathic skeletal hyperostosis as showing calcification or ossification along the anterior to anterolateral aspect of four contiguous vertebral bodies with relative preservation of the height of the intervertebral disc in the affected areas, distinguishing it from degenerative discogenic disease. Neurological complications from OALL are rare. It typically affects males over 60 years of age. In this case report, early ossification of anterior longitudinal ligament was observed during routine skeleton examination of medico-legal case. The bones were of human male of about 25 to 30 year of age. The anterior longitudinal ligament over lower four thoracic vertebrae were fully ossified. This early complete ossification of the anterior longitudinal ligament signifies either malignancy or metabolic disorders. So, the knowledge of this anatomic variation would be helpful for early detection of different pathological conditions.

**Key words:** Anterior longitudinal ligament, Malignancy, Metabolic disorders, Ossification skeleton.

**Address for correspondence:** Dr. Shivpal V Tambe, Assistant Professor, Department of Anatomy, Government Medical College, Nagpur -440003, India.

Mob: +918888707352, +918888954813, E-mail: [shivtambe@gmail.com](mailto:shivtambe@gmail.com)

#### Introduction

Ossification and calcification of the ligaments have been widely investigated. Resnick et al and Resnick, Shaul and Robins coined the term diffuse idiopathic skeletal hyperostosis for Forestier's disease and ossification of the spinal ligaments has been considered as a part of this entity. They defined diffuse idiopathic skeletal hyperostosis as showing calcification or ossification along the anterior to anterolateral aspect of four contiguous vertebral bodies with relative preservation of the height of the intervertebral disc in the affected areas, distinguishing it from degenerative discogenic disease<sup>1, 2</sup>. Neurological complications from Ossification of the anterior longitudinal ligament (OALL) are rare. The most common symptoms of OALL are compression of the oesophagus and trachea. Although fewer than 10% of patients require surgical decompression of these structures, aspiration pneumonia and

suffocation by aspiration of food have been described. It typically affects males over 60 years of age<sup>3</sup>. Radiologically OALL has been classified into three categories<sup>4, 5</sup>; Segmental, Continuous and Mixed types.

The diagnosis of diffuse idiopathic skeletal hyperostosis is often confused with ankylosing spondylitis and these are clinical entities with similar findings but different treatments<sup>4</sup>. In our case, we found complete continuous type of ossified anterior longitudinal ligament by around 25 to 30 years. This knowledge of anatomic variation will be useful for clinicians for diagnosis of various disorders.


#### Case Report

We routinely examine skeleton of unknown species, age, and sex which usually come to our department for medico-legal investigation in sealed parcels. One such parcel was opened and we noted the different bones in it. These were skull, mandible, and broken pieces of humerus,

tibia, femur, hip bone, ribs, vertebrae and the thyroid cartilage. After examining all the bones, it was found that the skeleton remains are of human male around 25 to 30 years of age. During investigation we observed fused lower five thoracic vertebrae. It was found to be ossified anterior longitudinal ligament. The

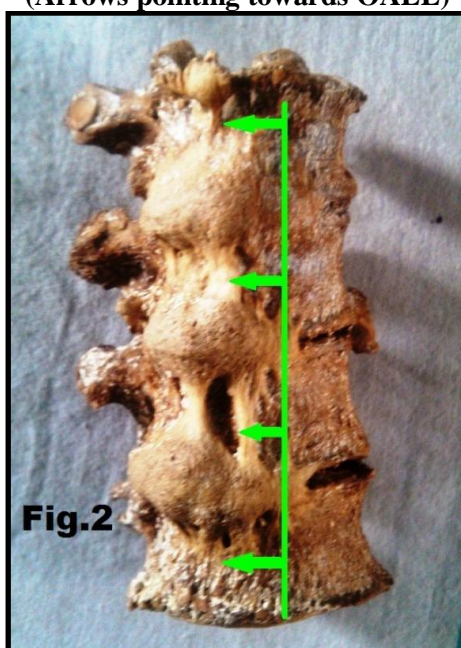
investigated skeleton was found to be of human being. It was of male skeleton of around 25 to 30 years of age. We noted complete ossification of anterior longitudinal ligament in lower four thoracic vertebrae on right side in the skeleton remains (Figure 1 & 2).

**Figure-1: Horizontal line spanning over lower 4 thoracic vertebra  
(Arrows pointing towards OALL)**



**T9- 9<sup>th</sup> Thoracic Vertebra, T10- 10<sup>th</sup> Thoracic Vertebra, T11- 11<sup>th</sup> Thoracic Vertebra, T12-12<sup>th</sup> Thoracic Vertebra**

**Figure-2: Vertical line spanning over lower four thoracic vertebrae  
(Arrows pointing towards OALL)**



## Discussion

Diffuse idiopathic skeletal hyperostosis (DISH) has long been regarded as a radiological entity manifesting flowing ossification adjacent to the

anterior and lateral borders of at least four contiguous vertebral bodies, maintenance of disc spaces, and a dearth of bony ankylosis and erosion of the apophyseal and sacroiliac joints. In the majority of cases, this entity shows an innocuous clinical course and the dysphagia shown has also been documented<sup>6,7,8</sup>.

It affects older men predominantly older than 60 years of age. The disease is usually asymptomatic; however, dyspnea, dysphagia, spinal cord compression, and peripheral nerve entrapment have all been documented in association with the disorder. Some of the symptomatic patients presented with dysphagia due to esophageal compression by calcified anterior longitudinal ligaments, and another patient developed recurrent spinal stenosis when scar tissue from a previous decompressive laminectomy became calcified. Dysphagia may result from inflammatory changes that accompany fibrosis in the wall of the esophagus or from esophageal denervation. Evaluation of dysphagia even in the presence of Forestier's disease must rule out occult malignancy<sup>5</sup>. Diffuse idiopathic skeletal hyperostosis and ankylosing spondylitis are difficult to distinguish from one another. Pathologically, diffuse idiopathic skeletal hyperostosis differs from ankylosing spondylitis. Clinically, however, both are similar. Diffuse idiopathic skeletal hyperostosis has even been referred to as a "senile ankylosing spondylitis." Ankylosing spondylitis, a chronic inflammatory rheumatic disease, tends to affect relatively young white males. Classically, it is associated with sacroiliac and/or apophyseal fusion or sclerosis. Patients with ankylosing spondylitis are symptomatic and suffer from a myriad of associated conditions such as iritis, uveitis, or ulcerative colitis. In contrast, patients with diffuse idiopathic skeletal hyperostosis tend to be asymptomatic. However, findings such as dysphagia from esophageal impingement, spinal cord compression, and peripheral nerve entrapment have been attributed to this form of ankylosis. In practice, most patients are diagnosed after trauma and associated severe neurological deficits, such as quadraparesis or quadriplegia. Even trivial trauma, such as a minor fall or a syncopal episode, may be associated with severe neurological deficits in these individuals. Inevitably, the diagnosis of diffuse idiopathic skeletal hyperostosis is confused with ankylosing spondylitis, but focus on the features that help differentiate it from ankylosing spondylitis<sup>9,10,11</sup>. Mizuno J et al<sup>12</sup> reported two cases. In 1<sup>st</sup> case- a male patient of 63-year developing progressive dysphagia and rhinolalia, cervical X-rays and

CT showed flowing OALL in the entire cervical spine. MRI demonstrated displacement of the trachea and esophagus by this mass. There was OALL in the thoracic and lumbar spine. In another male patient of 62 year old who had undergone removal of ossification of the posterior longitudinal ligament (OPLL) from C2 to C5. He developed dysphagia and myelopathy. Cervical X-rays and CT demonstrated projection of OALL as well as posterior osteophytes at C5/6. MRI suggested that OALL had caused dysphagia, and osteophytes deteriorated myelopathy. Removal of OALL was carried out in these two cases. In case 2, removal of the osteophytes and herniated disc was carried out at the same time. Postoperative course was unremarkable with improvement of symptoms. Treatment of dysphagia due to OALL is considered to be conservative. However, surgical decompression should be considered in cases of marked projection of OALL obstructing the esophagus<sup>12</sup>. The patient of DISH developed dysphagia because of oesophageal compression with ossification of the anterior longitudinal ligament (OALL) and radiculomyelopathy due to associated stenosis of the cervical spine. The diagnosis of OALL was made by plain lateral radiography and classified into three types; segmental, continuous and mixed. Some patients had associated OALL in the thoracic and lumbar spine without ossification of the ligamentum flavum. Because symptomatic OALL may be associated with spinal stenosis, precise neurological examination is critical. A simultaneous microsurgical operation for patients with OALL and spinal stenosis gives good results without serious complications. Although ossification of the posterior longitudinal ligament (OPLL) is associated with radiculomyelopathy, ossification of the anterior longitudinal ligament (OALL) has not been widely described since it is rarely symptomatic. Resnick et al and Resnick, Shaul and Robins coined the term diffuse idiopathic skeletal hyperostosis for Forestier's disease and ossification of the spinal ligaments has been considered as a part of this entity. The management of symptomatic OALL is still controversial. Although conservative treatment with anti-inflammatory medication may be effective, aspiration pneumonia has been

described—and there may be myelopathy due to coexisting spinal stenosis<sup>4</sup>

In our case report, we determined the approximate age of the deceased by examining all bones in the skeleton which came to our department for medicolegal investigation and it was found to be around 25-30 years. We observed ossified anterior longitudinal ligament on right side of vertebral body (Figure 1 & 2) as the ossification never complete by this age, it might be pathological either due to metabolic disorders or malignancy. So, the knowledge of this anatomical variation would be useful for the clinicians to interpret different clinical conditions.

## Conclusion

From the above medico-legal case examination, it is concluded that there is early (25 to 30 years of age) ossification of the Anterior longitudinal ligament in lower four thoracic vertebrae and it was on right side of the vertebral body. This ossification might be the component of Diffuse Idiopathic Skeletal Hyperostosis (DISH). Generally ossification of Anterior Longitudinal Ligament is found around sixty years of age. There is scarcity of data in Indian population, so this anatomical variation would be useful while treating the patients of musculoskeletal disorders and for interpretation different clinical conditions.

*Source(s) of support: Nil*

*Conflict of Interest: None declared*

## References

1. Resnick D, Shapiro RF, Wiesner KB, et al. Diffuse idiopathic skeletal hyperostosis (DISH) (ankylosing hyperostosis of Forester and Rotes-Querol). *Semin Arthritis Rheum* 1978;7:153–87. [PubMed]
2. Resnick D, Shaul SR, Robins JM. Diffuse idiopathic skeletal hyperostosis (DISH): Forestier's disease with extraspinal manifestations. *Radiology* 1975;115:513–24. [PubMed]
3. Hamidreza Aliabadi, David Biglari, L. Fernando Gonzalez, Peter Nakaji. Diffuse Idiopathic Skeletal Hyperostosis versus Ankylosing Spondylitis: Brief Case Review. *Barrow Quarterly* 2006; 22(4):10-14.
4. J Mizuno, H Nakagawa, J Song. Symptomatic ossification of the anterior longitudinal ligament with stenosis of the cervical spine: A report of seven cases. *British Editorial Society of Bone and Joint Surgery*,2005;87(10):1375-1379. [PubMed]
5. McCafferty RR, Harrison MJ, Tamas LB, Larkins MV. Ossification of the anterior longitudinal ligament and Forestier's disease: an analysis of seven cases. *J Neurosurg* 1995;83:13–17. [PubMed]
6. Kobayashi T, Hida K, Iwasaki Y, et al. Dysphagia due to ossification of anterior longitudinal ligament with diffuse idiopathic skeletal hyperostosis (DISH): two cases report. *Spinal Surg* 1999;13:197–201.
7. Epstein N, Hollingsworth R. Ossification of the cervical anterior longitudinal ligament contributing to dysphagia: case report. *J Neurosurg* 1999;90(Suppl 2):261–3. [PubMed]
8. Kristensen S, Sander KM, Pedersen PR. Cervical involvement of diffuse idiopathic skeletal hyperostosis with dysphagia and rhinolalia. *Arch Otorhinolaryngol* 1988;245(6):330-4. [PubMed]
9. Oga M, Mashima T, Iwakuma T, Sugioka Y. Dysphagia complications in ankylosing spinal hyperostosis and ossification of the posterior longitudinal ligament: roentgenographic findings of the developmental process of cervical osteophytes causing dysphagia. *Spine* 1993;18(3):391–4. [PubMed]
10. Suzuki K, Ishida Y, Ohmorik K. Long term follow-up of diffuse idiopathic skeletal hyperostosis in the cervical spine: analysis of progression of ossification. *Neuroradiology* 1991;33:427–31. [PubMed]
11. Forestier J, Rotes-Querol J. Senile ankylosing hyperostosis of the spine. *Ann Rheum Dis* 1950;9:321–30. [PubMed]
12. Mizuno J, Nakagawa H, Isobe M. Dysphagia caused by ossification of the posterior longitudinal ligament associated with diffuse idiopathic skeletal hyperostosis: report of two cases. *No Shinkei Geka* 1998;26:67–72. [PubMed]