

CASE REPORT

Situs Inversus Totalis- A Case Report

Rolly Kaushik¹, Kunal Chandrakar², DD Ksheersagar³, Purvi Mishra⁴, Dharmendra Mishra⁵

1- Junior Resident 2 of Anatomy, NKP Salve Institute of Medical Sciences & Research Centre, Nagpur

2- DNB Senior Resident of Radiology, CM Medical College, Durg, C.G.

3- Professor & HOD of Anatomy, NKP Salve Institute of Medical Sciences & Research Centre, Nagpur

4- Associate Professor of Anatomy, NKP Salve Institute of Medical Sciences & Research Centre, Nagpur

5- Professor & HOD. Department of Skin & VD, Indira Gandhi Government Medical College, Nagpur

<http://dx.doi.org/10.18049/jcmad/319a23>

Abstract

Situs Inversus Totalis is a rare congenital recessively inherited condition in which there occurs transposition of all viscera with right sided heart (dextrocardia) in a mirror image form. The term Situs Inversus is of Latin origin meaning inverted position of the internal organs. Generally individuals With Situs Inversus Totalis are asymptomatic and have a normal life expectancy. Many people with Situs Inversus Totalis are unaware of their anatomical variation, which may be detected when subjects seeks medical attention for some condition. The reversal of the organs may lead to some confusion in diagnosis and management as many signs and symptoms will be on the reverse side. We present here with a case report of a 28 years old male patient reported to the Department of Medicine with complain of high grade fever for 1 week. The Chest X-ray, Ultrasonography, CT scan and MRI were done and he was diagnosed as Situs Inversus Totalis.

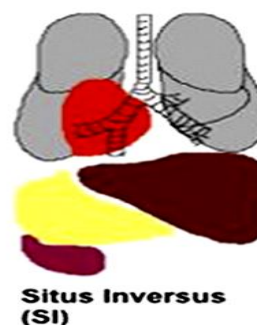
Keywords: Situs Inversus Totalis, Dextrocardia.

Address for correspondence: Dr. Rolly Kaushik, Vindhyachal Hostel, NKP Salve Institute of Medical Sciences & Research Centre, Nagpur. Email: kaushik.rolly@gmail.com Mob: 08975109020

Introduction

Situs Inversus is a congenital condition in which all visceral organs are reversed from their normal position and when associated with right sided (dextrocardia) it is referred as Situs Inversus Totalis¹. Except for anomaly of position the hearts of such individuals remain normal^{2,3}. When Situs Inversus is accompanied by sinusitis and bronchiectasis, it constitutes Kartagener Syndrome⁴. Situs inversus is generally an autosomal recessive genetic condition, sometimes it can be X-linked and also found in identical twins. Situs Inversus Totalis has been estimated to occur once in about 6000 - 8000 live births⁵. This condition affects all major organs within the thorax and abdomen the organs are simply transposed through the sagittal plane. The heart is relocated on the right side of the thorax, the stomach and spleen on the right side of the abdomen and the liver and gallbladder on left side. The left lung is trilobed and right lung is bilobed. The blood vessels,

nerves, lymphatics and intestines are also transposed. However relationship between the organs is not changed, so functional problems rarely occur⁵. Generally, patients with Situs Inversus Totalis are asymptomatic and lead a normal life in most cases.



Case Report

A 28 years old male patient admitted with chief complaints of high grade fever, yellowish discoloration of sclera and urine and easy fatigability. He had no history of hypertension,

diabetes mellitus, bronchial asthma and any previous surgery.

On General Examination

- Patient was pale (Anemic)
- Icterus present.
- Blood pressure recorded was 110/80mmHg.
- On auscultation S₁, S₂ heard in right 5th intercostal space.

Investigations:

- Haemoglobin-7.3 gm% ,
- Platelet count-65,000/cumm,
- Serum bilirubin-31.23mg/dl,
- Blood urea-282.8mg/dl,
- Serum creatinine-7.01mg/dl,
- HbsAg-Negative,
- HIV- Non reactive.
- X-ray chest PA view- showed Dextrocardia

Abdominal Ultrasonography

- Complete Situs Inversus noted
- B/L Enlarged kidney with acute parenchymal affection changes
- Mild Hepatosplenomegaly
- Obstructive Left renal calculi

Discussion

The majority of literature published to date on embryologic factors predisposing to Situs Inversus Totalis focuses on abnormal development of the heart. Therefore, a discussion of the mechanisms controlling heart rotation and migration is relevant. Early in development, the embryo is symmetric, both sides being identical.^{6,7} The heart begins formation at approximately 18 days gestation with the appearance of paired cardiac tubes.^{6,8} At approximately 22 day of gestation, the cardiac tubes lengthen and rotate to the right. This is the first sign of asymmetry in the embryo.⁹ The rotation of the heart, which is often called looping, is one of the most important steps in formation because it determines the structure of two separate systems for pumping blood.⁷ The apex of the heart moves from the right side of the thorax to the left side in the next 10 -12 days, by which time most of the heart lies in the left chest.⁸ Dextrocardia results when the heart fails to migrate to the left thorax. Situs inversus totalis results when the cardiac tubes rotate to the left

and the placement of the heart and other internal organs presents a mirror image of the normal arrangement. In other words, the liver is in the left abdomen, the stomach is in the right abdomen, the trilobed lung is in the left chest, and the bilobed lung is in the right chest.

The exact mechanism that controls rotation and migration of the internal organs, or left-right asymmetry, is unknown. Research has concentrated on the looping of the heart because it is believed that this organ is the “most sensitive to abnormalities” It is also believed that the rotation of the heart initiates the process of rotation and migration of the abdominal organs.¹⁰ Molecular signaling and left-right asymmetry research has been conducted on chick embryos, which are similar to the embryos of other vertebrates. The current view among researchers is that organ rotation and migration are the result of a chain of signals. Secretion of a protein named “Sonic hedgehog” (Shh) influences the expression of two transforming growth factors referred to as Nodal and Lefty. When these proteins are secreted on the left side of the embryo, the heart loops to the right, resulting in situs solitus. If the Shh protein is secreted on the right side, the heart loops to the left, resulting in situs inversus.^{7,11} If the Shh protein is secreted on both sides, the signal is unclear; 50 percent of such cases will result in situs solitus and 50 percent will result in situs inversus. However, it remains uncertain what causes the production of the Shh protein.⁷ Situs inversus tends to be familial. This led researchers to believe that a gene is responsible for this abnormality. Recently, a gene called Pitx2 has been identified as controlling the secretion of Shh and Nodal. Pitx2, Shh, and Nodal all appear on the left side of the heart in the chick embryo and are produced throughout development. Researchers have manipulated and inserted the gene and successfully produced chicks with situs inversus and situs ambiguous.^{7,11} Exactly how the signals are given and where they begin is uncertain, but it is believed that they begin in the midline of the notochord.¹¹

Conclusion

The etiology of Situs Inversus Totalis remains unclear. However, the literature establishes that isolated Situs Inversus Totalis is usually

asymptomatic. This case study illustrates the importance of physical assessment skills in Identifying Situs Inversus Totalis. Correct diagnosis is crucial for interpretation of future symptoms and other diagnostic procedures. It may have implication especially during surgical procedures in preventing unintentional operative complications.

Conflict of Interest: None declared

Source of Support: Nil

Ethical Permission: Obtained

References

1. Applegate KE, Goske MJ, Pierce G, Murphy D. Situs revisited. Imaging of heterotaxy Syndrome. Radiographics 1999;19 (4): 837-852. [PubMed] <http://dx.doi.org/10.1148/radiographics.19.4.g99j131837>
2. Gutgesell HP. Cardiac malposition In: Garson AG Jr, Fisher DJ, Neish SR (eds). Science and Practice of Pediatric Cardiology. Vol 2.2nd ed. Williams & Wilkins: 1998: 1539-1561.
3. Harler DJ, O' Leary PW: Cardiac malpositions and abnormalities of atrial and visceral situs In: Emmanouilides GC, Riemenschneider TA, Allen HD, Gutesell HP (eds). Heart Disease in Infants, Children, Adolescents. 5th ed. Vol 2. Williams & Wilkins; 1995: 1307-1336.
4. Kobzik L. The Lung. In Robbin's Pathologic Basis of Disease ed. by Cotran, Kumar and Collins. Pub. by W.B. Saunders Co., Philadelphia, In India by Harcourt India Pvt. Ltd., New Delhi. 6th Ed. 2000: 7-16.
5. G.Supriya, S.Saritha, Seema Madan, Situs Inversus Totalis - A Case Report. Journal of Applied Physics. 2013;(3)6: 12-16.
6. Spoon & Janie, Situs Inversus Totalis. Neonatal Network, 2001; 1(2):63-65.
7. Izipisua Belmonte JC, How the body tells left from right. Sci America. 1999;280(6):46-51. [PubMed] <http://dx.doi.org/10.1038/scientificamerican.0699-46>
8. Boulda TF and Tonlin ILD, Cine and Digital subtraction angiography in Tonkin ILD, Pediatric Cardiovascular Imaging. Philadelphia, WB Saunders 1992: 83-176.
9. Splitt MI³, Burn J, and Goodship J. Defects in the determination of left-right asymmetry. Journal of Medical Genetics.1996; 33(6): 498-503. [PubMed] <http://dx.doi.org/10.1136/jmg.33.6.498>
10. Levin, M. and Nascone, N. Two molecular models of initial left-right asymmetry generation. Med. Hypotheses. 1997; 49: 429-435. [PubMed] [http://dx.doi.org/10.1016/S0306-9877\(97\)90092-X](http://dx.doi.org/10.1016/S0306-9877(97)90092-X)
11. Srivastava D. Left, right. Which way to turn? Nature Genetics. 1997; 17 (3): 252-254. [PubMed] <http://dx.doi.org/10.1038/ng1197-252>

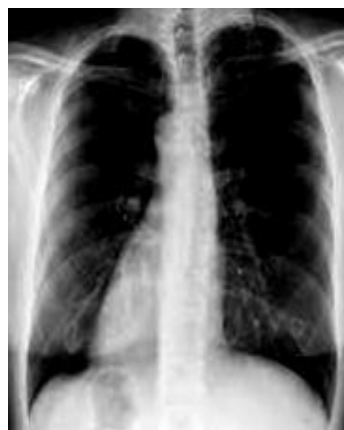

Figure 1: PA view of chest (Dextrocardia)

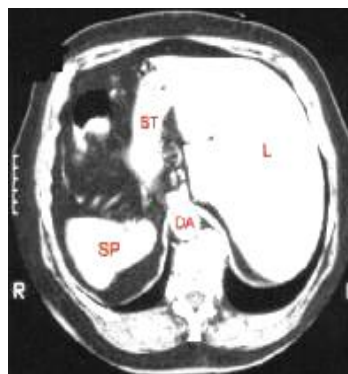


Figure 2: CT scan showing reversal of normal anatomy