

ORIGINAL ARTICLE

Oral submucous fibrosis and iron deficiency anemia: A clinical study

Ahire Sushil Lamlakar ¹, Rajole Mahendra Parashram ²

1, 2- Associate Professor, Dept of Pathology, SMBT Institute of Medical Sciences and Research Centre Nandi-Hills, Dhamangoan, Nashik.

Abstract

Background: Oral submucous fibrosis (OSMF) is a potentially malignant disorder and crippling condition of oral mucosa. It is a well-recognized chronic insidious disease, precancerous condition, autoimmune and collagen related disorder which is multifactorial in origin associated with betel quid chewing characterized by progressive hyalinization of the lamina propria. It causes Significant hematological abnormalities resulting in anemia and a decrease in serum iron levels. **Methods:** Forty-five patients clinically diagnosed with OSMF and confirmed histopathologically without any other systemic disease constituted the study group. 45 age and sex matched healthy subjects constituted the control group. Hemoglobin and serum iron levels were estimated by Sahli's and Ferrene methods respectively. **Results:** The OSMF group showed significantly lower levels of hemoglobin and serum iron in comparison with the healthy control group. The above results establish the fact that serum iron level is an important marker for OSMF and the levels of which could be used to predict the prognosis and progression of the condition to malignancy with greater accuracy. **Conclusion:** The finding of the present study focusses on the assessment of hemoglobin and serum iron for patients with oral submucous fibrosis. Also iron therapy should be instituted concomitantly with the initial diagnosis which helps to cease the further progression of the condition. Further extensive studies are indicated to understand the correlation between Oral submucous fibrosis and iron deficiency anemia.

Keywords: Oral Submucous Fibrosis, Iron deficiency anemia, Serum Iron, Serum hemoglobin.

Address for correspondence: Dr Ahire Sushil Lamlakar Associate Professor SMBT Institute of Medical Sciences And Research Centre Nandi-Hills, Dhamangoan, Tal- Igatpuri Dist. Nashik Maharashtra. Email: ahire.sushil96@gmail.com

Received on : 10/12/2016 Revised : 29/12/2016 Accepted : 10/01/2016

Introduction

Oral submucous fibrosis (OSMF) is a chronic, progressive, disabling, scarring, precancerous condition of the oral mucosa which was first described by Schwartz in 1952 among five East African women of Indian origin under the term atropica idiopathica (tropica) mucosae oris. It is also known as idiopathic scleroderma of the mouth, idiopathic palatal fibrosis, sclerosing stomatitis, diffuse oral submucous fibrosis and submucous fibrosis of the palate and pillars.¹ OSMF has been documented in the Indian population since the time of Sushruta- a renowned Indian physician (circa sixth century BCE) as Vidari, the features of which simulate.² Submucous fibrosis is an insidious, chronic disease affecting any part of the oral cavity and

sometimes the pharynx. Occasionally it is preceded by and/or associated with vesicle formation and is always associated with a juxta-epithelial inflammatory reaction followed by progressive hyalinization of the lamina propria. The later subepithelial and submucosal myofibrosis leads to stiffness of the oral mucosa and deeper tissues with progressive limitation in opening of the mouth and protrusion of the tongue, thus causing difficulty in eating, swallowing and phonation. Epithelial atrophy is marked in advanced stages of the disease.³ Apparent divergencies in these characteristics between groups of patients in different studies raised the question whether OSMF should be considered as one, or more than one disease. Although the evidence that it predisposes to cancer is not yet absolutely conclusive, it is

highly probable that this relationship exists. The WHO definition for an oral precancerous condition-a generalized pathological state of the oral mucosa associated with a significantly increased risk of cancer-accords well with the characteristics of OSMF.³ OSMF is also considered as an Asian version of Sideropenic dysphagia, wherein chronic iron deficiency leads to mucosal susceptibility to irritants, such as areca nut products.⁴ Hemoglobin levels as well as serum iron levels, are considered as biochemical indicators for nutritional assessment.^{5,6} Thus, the present study is undertaken to comprehend the association between OSMF and iron deficiency anemia by estimating the levels of hemoglobin and serum iron in patients diagnosed with oral submucous fibrosis and comparing the values with that of healthy subjects.

Materials & Methods

This study was conducted over a period of 2 years in clinically diagnosed and histopathologically proven patients of OSMF. Patients with habit of chewing areca nut or one of its commercial preparations, with the presence of burning sensation, inability to consume spices, stiffness of buccal mucosa, vesicle formation, ulceration, and blanching of oral mucosa were included in the OSMF group.

Exclusion criteria

Patients with any systemic complications, suffering from any major illness, Habit of chewing only tobacco, Patients with habit chewing areca nut or one of its commercial preparations but without OSMF.

Fifteen healthy individuals, matched for gender and age, without any history of habit of chewing areca and tobacco and any major illness in recent past were included as controls. Subjects with any habits and suffering from any systemic disease in the recent past were excluded from the control group. Institutional ethical clearance and informed consent was obtained from the individuals who participated in the study. Five mL of fasting venous blood was collected and submitted for the estimation of hemoglobin levels by using Sahli's method and serum sample for serum levels of iron by using Ferrene method.

Results

The OSMF study group patients were comprised of 45 patients of age group ranging from 16 to 46 years with a mean age of 16.45 ± 6.78 years. The mean hemoglobin levels in control group were $14.2 \pm$ mg/dl, whereas those of OSMF group were $10.53 \pm$ mg/dl. Comparison of the hemoglobin levels between control group and the OSMF patients showed highly significant difference ($p < 0.001$, Student's t test). (Table 1)

Table 1: Comparison of the hemoglobin levels between control group and the OSMF patients using student's t test.

Group	Cases (n)	Hb levels (Mean±SD)	P value
Control group	45	$14.2 \pm$	$P < 0.001^*$
OSMF group	45	$10.53 \pm$	

* significant

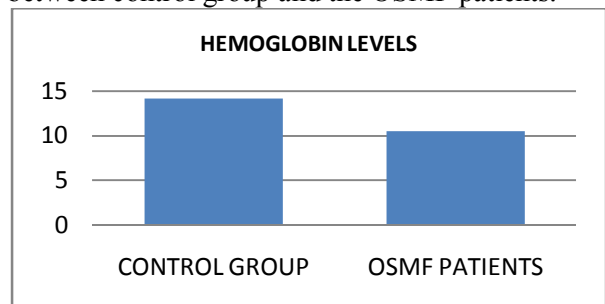
The serum iron levels in control group were $138.20 \pm$ and in OSMF patients were $66.26 \pm$. Comparison of the serum iron levels between control group and the OSMF patients also showed highly significant difference ($p < 0.001$, Student's t test). (Table 2)

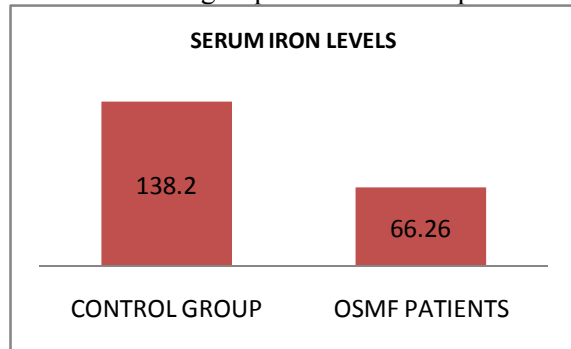
Table 2: Comparison of the serum iron levels between control group and the OSMF patients using student's t test.

Group	Cases (n)	Serum iron levels (Mean±SD)	P value
Control group	45	$138.20 \pm$	$P < 0.001^*$
OSMF group	45	$66.26 \pm$	

* $P < 0.001$ = statistically highly significant. SD = Standard deviation.

Graph 1: Comparison of the hemoglobin levels between control group and the OSMF patients.



Graph 2: Comparison of the serum iron levels between control group and the OSMF patients.

Discussion

When OSMF was first described in 1952, it was classified as an idiopathic disorder. Later on many researchers put forward various hypothesis suggesting that OSMF is multifactorial origin with possible etiological factors to date are areca nut, capsaicin in chilies, micronutrient deficiencies of iron, zinc and essential vitamins. In addition, a possible autoimmune basis to the disease with demonstration of various auto-antibodies and an association with specific HLA antigens has also been proposed.²

It has been suggested that oral submucous fibrosis is caused due to the action of arecoline. Arecoline not only stimulates fibroblast proliferation and collagen synthesis, but also decreases its breakdown by forming more stable collagen structure. So there is more collagen availability leading to OSMF.⁴

Soluble irritants, such as alkaloids present in areca nut act as initiating factors causing a juxta-epithelial inflammatory reaction thus leading to burning sensation, vesiculation and ulceration of the oral mucosa, which renders a phase for difficulty in consumption of the normal diet leading to poor nutrition. Deficiency of Vitamin B complex, iron and other trace elements due to nutritional depletion could possibly initiate anemia and altered cell mediated immunity, which in turn acts as a promoting factor to this pre-existing pathologic response of the lamina. After a frank establishment of the lesion, anemia may further perpetuate by inadequate intake of food due to fibrosis and trismus, thus becoming a vicious cycle.^{6,7}

Nutritional deficiencies, primarily of iron and vitamins, are implicated in the etiology of OSMF. Iron is essential for the overall integrity and health of epithelia of digestive tract and its contribution to normal enzymatic functions. OSMF is also considered as an Asian version of sideropenic dysphagia, wherein chronic iron deficiency leads to mucosal susceptibility to irritants, such as chilies and areca nut products.^{4,7} Hemoglobin levels, in particular serum iron levels, are considered as biochemical indicators for nutritional assessment.^{5,7,8} In the present study, OSMF group shows significant lower levels of hemoglobin and serum iron on comparison with the values of the control group. Studies with similar results are reported by Rupak S et al⁶, Anuradha CD et al⁹, Hegde K et al⁷, Ganapathy KS et al¹⁰ and Khanna SS et al¹¹. Cytochrome oxidase is an iron-dependent enzyme which is required for the normal maturation of the epithelium. In iron deficiency state, the levels of cytochrome oxidase are low, consequently leading to epithelial atrophy. An atrophic epithelium makes the oral mucosa vulnerable to the soluble irritants. Fibrosis dictates that OSMF is basically a disorder of collagen metabolism. Hydroxyproline is an amino acid found only in collagen, which is incorporated in the hydroxylated form. This hydroxylation reaction requires ferrous iron and ascorbic acid. Utilization of iron, for the hydroxylation of proline and lysine, leads to decreased serum iron level. In OSMF patients, there is an increase in the production of highly cross-linked insoluble collagen type I loss of more soluble procollagen type III and collagen type VI. The cross-linking of collagen due to the upregulation of lysyl oxidase, plays a crucial role in the development and progression of the condition.^{6,7,8}

Although OSMF and iron deficiency anemia exist as separate conditions, the clinical findings of OSMF mimic those of iron deficiency anemia, which includes blanching, burning sensation, and dysphagia. Epithelial atrophy occurs due to a qualitative and quantitative defect in the oxygen and nutrient perfusion of the lamina propria and the overlying mucous membrane. The effect of soluble irritants on the atrophic epithelium, which ensues in due course, leads to malignancy. Thus, this unclear line of demarcation still persists, which calls upon for

further extensive studies to understand the correlation between OSMF and iron deficiency as well as the validation of serum iron levels in various stages of OSMF, as an indicator of malignant transformation.^{6,7,8}

Conclusion

The present study mainly focusses on the assessment of the hemoglobin and serum iron in OSMF patients. It is suggested that the biochemical assessment of oral precancerous conditions may help in early diagnosis and prognosis. It also serves in predicting the malignant potential, especially in high-risk groups. It is also of key importance that iron therapy should be instituted parallel with the initial diagnosis along with a proper balanced diet, as a part of the overall treatment of oral submucous fibrosis with other modes of treatment. This helps to stop the further progression of the condition.

Conflict of Interest: None declared

Source of Support: Nil

Ethical Permission: Obtained

References

1. Bansal SK, Leekha S. Biochemical changes in OSMF. *J Adv Med Dent Scie* 2013;1(2):101-5.
2. Gupta M, Mishra P, Shrivastava K, Singh N. Oral Submucous Fibrosis- Current Concepts of etiology & its Management *J App Dent Med Sci* 2015;1(1):28-39.
3. Rajendran R. Oral submucous fibrosis: etiology, pathogenesis, and future research. *Bulletin of the World Health Organization*, 1994, 72 (6):985-96.
4. Kumar S, Mohan C, Pagrani M, Srivastava A. Oral submucous fibrosis – revisited. *Annals of Dental Specialty* 2014;2(2):43-6.
5. Ali FM, Prasant MC, Patil A, Aher V, Tahsildar S, Deshpande R. Oral Submucous Fibrosis: Medical Management. *Global Journal of Medicine and Public Health* 2012;1(1):12-9.
6. Rupak S, Baby GG, Padiyath S, Kiran Kumar KR. Oral submucous fibrosis and iron deficiency anemia relationship revisited- results from an Indian study. *e-Journal of Dentistry* 2012;2(2):159-65.
7. Karthik Hegde, Harshkant Gharote, Preeti Nair, Kavita Agarwal, Nisheeth Saawarn, Divyashree Kalyanpur. Iron Deficiency in Oral Submucous Fibrosis: Accelerator or a Promoter? *International Journal of Oral & Maxillofacial Pathology*; 2012;3(1):2-7.
8. Hegde K, Nair P, Gharate HP, Agarwal K, Bhat GR, Rajaram DK. Role of Hemoglobin and Serum Iron in Oral Submucous Fibrosis: A Clinical Study. *The Scientific World Journal* 2012, Article ID 254013, 5 pages.
9. C. D. Anuradha and C. S. Devi, “Serum protein, ascorbic acid & iron & tissue collagen in oral submucous fibrosis—a preliminary study,” *The Indian Journal of Medical Research*, vol. 98, pp. 147–151, 1993.
10. Ganapathy KS, Gurudath S, Balikai B, Ballal S, Sujatha D. Role of Iron Deficiency in Oral Submucous Fibrosis: An Initiating or Accelerating Factor. *Journal of Indian Academy of Oral Medicine and Radiology* 2011;23(1):25-8.
11. S. S. Khanna and F. R. Karjodkar, “Circulating immune complexes and trace elements (Copper, Iron and Selenium) as markers in oral precancer and cancer : a randomised, controlled clinical trial,” *Head & Face Medicine*, vol. 2, p. 33, 2006.