

ORIGINAL ARTICLE

Cystic Lung Diseases in Pediatric Age Group with Clinicopathological and Radiological Correlation

Pritam S Khairkar¹, Megha Pandey², Meenakshi Balasubramanian³ and Ashish Pandey⁴

1- Associate Professor (Pathology), Chirayu Medical College and Hospital, Bhopal, India

2- Assistant Professor (Pathology), Chirayu Medical College and Hospital, Bhopal, India

3- Associate Professor (Pathology), TNMC & BYL Nair hospital, Mumbai, India

4- Assistant Professor (Pathology), Chirayu Medical College and Hospital, Bhopal, India

Abstract

Introduction: Cystic lesions in lung are uncommon findings. They include rare congenital cysts and acquired cysts. The clinical features, morphology, treatment and prognosis are different in these cysts and thus a confident diagnosis should be made. The study aims to identify cystic lesions of lung in children and study their clinical, radiological and histopathological features.

Material & Methods: 39 patients below 15 years were evaluated. Lung cysts diagnosed either clinically or radiologically were included in the study only if the tissue (specimen) was available. We compared the clinical, radiological and final histopathological diagnosis of the cases.

Results: The various cysts studied in the study were bronchiectasis (41.02%), hydatid cyst (33.3%), congenital lobar emphysema (7.69%), congenital cystic adenomatoid malformation (5.12%), Pneumatocele (5.12%), bronchogenic cyst (5.12%) and simple lung cyst (2.56%). Males (61.5%) were affected more than females (38.4%). Left lung was affected in 16 cases while right in 23 cases and 04 had bilateral involvement. Children between 11 to 15 years were commonly affected (7 cases). **Conclusion:** lung cysts in children are a rare group of disorders which can be congenital or acquired. Acquired cysts were more common than congenital cysts. Careful attention should be paid to clinical features, radiological findings and gross and microscopic findings of the cysts for their accurate diagnosis.

Keywords: Cyst, lung diseases, Bronchiectasis, Hydatid cyst, Pediatric age group

Address for correspondence: Pritam S Khairkar, Associate Professor (Pathology), Chirayu Medical College & Hospital, Bhopal-Indore Highway, Bhopal. M.P. India. Mobile No. +91 7738247822.

Email: dr_pritam2006@yahoo.co.in, ashishpandey_789@yahoo.com, drmeghashukla@yahoo.com

Received on :28/05/2016 Revised :02/06/2016 Accepted : 08/06/2016

Introduction

Lung pathology in the pediatric age group can often present as cyst in the lung. Many varieties of cysts occur in the lungs, majority of them are acquired but a minority of them result from developmental defects in air passages (congenital).^[1] The earliest report of a lung cyst, in a 3-month old child, was made by Fontanus in 1639.^[2] Lung cysts are mostly infective (acquired) in nature and include pneumatocele, bronchiectasis, hydatid cyst etc. The pathogenesis in cases of acquired lung cysts is varied, for example infections by micro-organism in pneumatocele,^[3] parasitic infection as in hydatid cyst.^[4] These can also be due to

obstruction to the bronchus, inflammation of the airway,^[5,6] and can have variable presentation.

Congenital lung cyst as the name suggests results from the faulty development of tracheobronchial tree. The first congenital lung cyst was reported by Morgagni in 1976^[1]. The congenital nature of the lung cyst may be difficult to prove. Many cysts are found within the first week or two of birth and in the absence of infection are accepted as congenital lesions.^[1] Numerous theories have been proposed for the development of congenital cysts. Primary agenesis of the ducts and alveoli, cyst formed by bronchial atresia or imbalance between the epithelial and mesenchymal growth are proposed for congenital cystic adenomatoid malformation. Dilatation of lymphatic spaces or

anomalous development of ventral foregut has been proposed for bronchogenic cyst.^[1,7]

Various classifications have been proposed for lung cysts but none of them are entirely satisfactory.¹ Until the formation of congenital cysts is better understood, all such classifications are only tentative and will require modification in the light of future work. The cyst can prenatally present with complications such as hydropsfetalis or it may be an incidental finding.^[1,8] Most of them present postnatally mostly during first few weeks of life as respiratory distress or can be asymptomatic.^[9] With increasing use of antenatal ultrasound and other radiological imaging, these cysts are being diagnosed early and the progression is being well followed up.^[8] The outcome of these cystic lung diseases is extremely variable with spontaneous regression^[8,10] to neonatal death.^[11,12] Many studies have been conducted to identify the prognostic factors and predictors of the outcome.^[11,12] The present study was undertaken to identify the spectrum of cystic lung diseases with clinical, radiological and histopathological correlation.

Materials and Methods

A retrospective study was undertaken wherein the case records of cystic lung diseases were retrieved from 1990 to 2004 from the department of pathology. The study also included the lung cyst of post mortem cases for the same period. Children between 0-15 years of age & of both the sexes were included in the study. Congenital as well as acquired lung cysts were included in the study. However, lung cysts diagnosed either clinically or radiologically were included in the study only if the tissue (specimen) was available. Clinical details and radiological findings were obtained from the case records of the patients. Detailed assessment of the clinical parameters was done like age, sex, clinical features, birth history, site of the cyst, size, clinical diagnosis, and routine investigations. Radiological findings included site, size, location and diagnosis/differential diagnosis. We compared the clinical, radiological and final histopathological diagnosis of the cases. Detailed gross and microscopic examination of the cyst was done in all cases. Any associated anomalies in lung or other organs were also noted. All sections were

stained routinely with Haematoxylin and Eosin. Special stains like PAS, Gomori's methenamine silver, Masson's trichrome, EVG, Brown and Brenn were used as per requirement.

Results

The present study encountered 39 cases of lung cysts in children between 0-15 years from 1990 to 2004. Amongst these male children (61.5%) were affected more than female children (38.4%). The most common cystic lesion of the lung in our study was bronchiectasis (41.02%). Left lung was affected in most of the cases with lower lobe being commonly involved (Table-1). Children above 5 years of age accounted for maximum number of cases (Table 2). Radiologically bronchiectasis was diagnosed in 7 cases (43.7%) while in rest the diagnosis was different (Table 3). Duration of symptoms ranged from 2 weeks to 5 years with an average of 2.6 years. Productive cough was the most common symptom and was present in all the cases of bronchiectasis.

Hydatid cyst was the second most common cystic lesion. Male children accounted for 69.2% cases while female children for 30.7% cases. The right lung was affected more commonly than left, while two cases had bilateral involvement (Table 1). Multiple cysts (53%) were more common than single cysts and all the cysts were unilocular. Children between 10- 15 years were most affected (Table 2). Radiology could diagnose hydatid cyst in 6 cases (Table 3). Common presenting symptoms were cough and breathlessness.

Two cases of congenital cystic adenomatoid malformation (CCAM) were seen, Both cases had left lung involvement and had equal sex distribution (Table 1). Both the patients presented before 1 year of age (Table 2). Radiologically CCAM was diagnosed only in one case (Table 3).

The study observed three cases of congenital lobar emphysema (CLE) with male to female ratio of 1:2. All the three cases had left lung involvement (Table 1) and were below 5 months of age. (Table 2) Radiology could diagnose CLE in two cases while one was given as overinflated lung. (Table 3) The duration of symptoms for all cases was less than 20 days with breathlessness as the most common presenting symptom.

Pneumatocele accounted for 5.12% cases (2 cases). Male to female ratio was 1:1 and had right lung involvement (Table 1). One case was diagnosed as pneumatocele on radiology and other as emphysematous bulla (Table 3). Breathlessness was common presenting symptom.

Table 1: Distribution of lung cysts

Disease	No of cases	Male	Female	Site of lung	Bilateral involvement
Bronchiectasis	16(41.02%)	10	6	Right-6, Left-8	2
Hydatid cyst	13(33.3%)	9	4	Right-8, Left-3	2
Congenital cystic adenomatoid malformation (CCAM).	2(5.12%)	1	1	Right-0, Left-2	0
Congenital lobar emphysema (CLE)	3(7.69%)	1	2	Right-0, Left-3	0
Pneumatocele	2(5.12%)	1	1	Right-2, Left-0	0
Bronchogenic cyst	2(5.12%)	1	1	Mediastinum	0
Simple lung cyst	1(2.56%)	1	0	Right-1, Left-0	0
Total	39	24(61.5%)	15(38.4%)		

Table 2: Age distribution of lung cysts

Disease	Age				
	< 6 months	6mths-1year	1-5yrs	5-10yrs	10-15yrs
Bronchiectasis(16)	1	0	5	3	7
Hydatid cyst(13)	0	0	2	4	7
Congenital cystic adenomatoid malformation (CCAM)(02)	0	2	0	0	0
Congenital lobar emphysema (CLE)(03)	3	0	0	0	0
Pneumatocele(02)	0	1	0	1	0
Bronchogenic cyst(02)	0	0	1	1	0
Simple lung cyst(01)	0	0	1	0	0
Total (39)	4	3	9	9	14

Table 3: Radiological diagnosis of various lung cysts

Histopathological diagnosis	Radiological diagnosis					
Bronchiectasis(16)	Bronchiectasis(7)	Fibrosis/collapse (4)	Cyst / cavity(2)	Lung abscess(1)	Fibrosis cavity(1)	/ TB with cavity(1)
Hydatid cyst(13)	Hydatid cyst (6)	Homogenous opacity(2)	Cystic lesion(2)	Cavity (abscess)(2)	? Sequestration(1)	-
Congenital cystic adenomatoid malformation (CCAM)(02)	? CCAM(1)	Pneumothorax with cyst (1)	-	-	-	-
Congenital lobar emphysema (CLE)(03)	CLE (2)	Overinflated lung (1)	-	-	-	-
Pneumatocele(02)	Pneumatocele (1)	Emphysematous bulla(1)	-	-	-	-
Bronchogenic cyst(02)	? Neurogenic tumor(1)	NAD(1)	-	-	-	-
Simple lung cyst(01)	Pneumothorax (1)	-	-	-	-	-

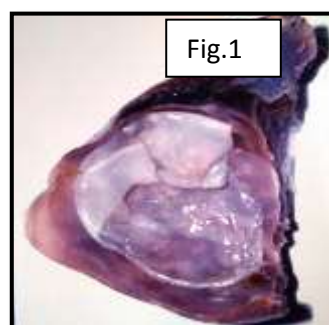
Two cases (5.12%) of bronchogenic cyst were observed in the study with equal sex distribution. One was 5 years and other was 8 years old. (Table 2) Radiologically, none of the cases was diagnosed (Table 3) both the cysts were unilocular. One case presented with fever and cough while other had discharging sinus over anterior chest wall. One case of simple lung cyst was seen in the study. The lesion was present in lower lobe of right lung. (Table 1 & 2) Radiologically it was labeled as pneumothorax. (Table 3)

Discussion

Cystic lung diseases are a rare group of conditions in children. The lung cysts have varied etiology and these may be either congenital or acquired with variable outcome. There are numerous classifications for cystic lung diseases but none are satisfactory and accepted. Confusion in classification of cystic lesions of the lung arises from controversies over the embryology, pathology, nomenclature and etiology of the different varieties of cysts.^[2] Of the total 39 cases, 24 (61.5%) were males and 15 (38.4%) were females. Various studies on cystic lung diseases^[8,11,13] have included only congenital cystic lesions but present study includes congenital as well as acquired lesions. In our study, the predominant cystic lesions were (acquired) infective. Bronchiectasis accounted for 41.02% cases while hydatid cysts were found in 33.33% of cases. The age group was variable. The youngest patient was of 1 month while the oldest was of 15 years of age. All the patients of congenital lesions were below 8 months of age, except those of bronchogenic and simple lung cysts. Fever, cough and breathlessness were common symptoms in infective group while breathlessness was common in congenital lesions. In Fields 1949 survey 92% of patients were below 10 years of age.^[6,14] In our study 6 cases were below 10 years and 7 cases were above 10 years of age. Although some studies recognize no sex predilection^[14] but in our study males were affected more (62.5%) than females (37.5%).

Cough is the most common symptom of bronchiectasis^[14] and it was present in 100 % of cases. Though cough with sputum production is the commonest mode of presentation it was

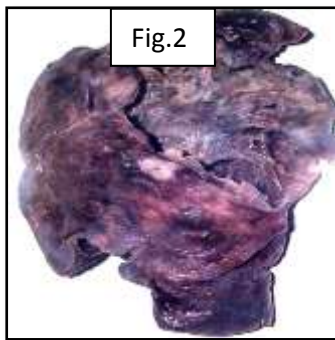
absent in 5 cases. The presence of dry cough can be explained on the basis of the bronchi being not heavily infected or the children swallowing the cough.⁶ The left main bronchus is two third the size of the right main bronchus. Hence it is readily obstructed so that the left lung, particularly the lower lobe is commonly involved, which is in line with previous observations.^[5,14,15] Bronchiectasis is bilateral in 18 - 41% of cases.^[15] Present study encountered 2 cases of bilateral bronchiectasis.



Hydatid cyst of lung is mostly solitary, however it can be multiple. In present study all cases of hydatid cyst were multiple but unilocular (Figure-1) This is consistent with findings of Kevin K et al & Nemir R L et al, who suggested that cysts caused by *E. granulosus* are unilocular and it is the most common infection but pulmonary involvement by *E. multilocularis* is very rare.^[8,16] Cough was the most common symptom and was present in 84 % of cases. This is in accordance with various studies which had cough as the common symptom.^[17,18] The main diagnostic tool for hydatid cyst is radiographic study. Radiology could make the diagnosis of hydatid cysts in 6 cases. The specific diagnosis of *E. granulosus* infection can be made by examination of aspirated fluid and we had opportunity in one case where we found scolices of *E. granulosus*.

Nemir R L et al mention that around 17 to 75 % of cystic hydatid disease cases occur in children.^[16] Nemir R L et al & Aydin A et al observed that mean age of presentation of pulmonary hydatid cysts in children was around 5 years.^[17,14] In contrast to the above studies, children between 10-15 years group were most commonly affected in our study. The right lung was affected more commonly (61.5 %) than the left. This was consistent with the finding in literature and various series which document a right side predominance^[18,19]

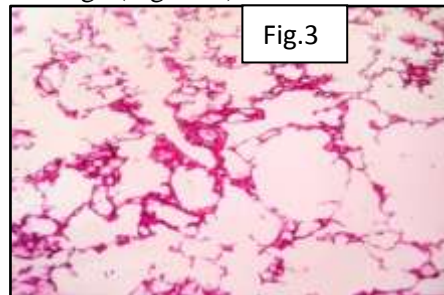
Congenital cystic adenomatoid malformation (CCAM) is a hamartomatous lesion of the lung and is a rare condition. Since it is a congenital lesion it usually presents immediately after birth or in the first few months of life. Majority of patients (83%) are diagnosed when they are younger than 6 months.^[12] In present study both the cases presented before 8 months of life. As observed by Julie A.M. et.al this condition is usually unilateral (95% cases) and commonly involves a single lobe (80-90% cases).^[12] Our study also observed that both the cases had single lesion confined to one lobe.(Figure-2)



The right and left side are equally affected, with lower lobe affected in about 60% of cases.^[20] In our study both the cysts were present on the left side and in lower lobe (Table 1). According to Stockers classification type I CCAM is the commonest lesion accounting for 65% of cases which presents as single or multiple large cysts. These large cysts are surrounded by smaller cysts.^[20] Both the cases in our study were of Stocker's type I and had single cyst. Grossly there were no smaller cysts surrounding the large cysts. Kuojen T et al in their study found that more than 45% of cases displayed segments of mucus cells in the lining of the wall which can undergo malignant change.^[21] Mucus cells were present in the lining of the cysts in both the cases.

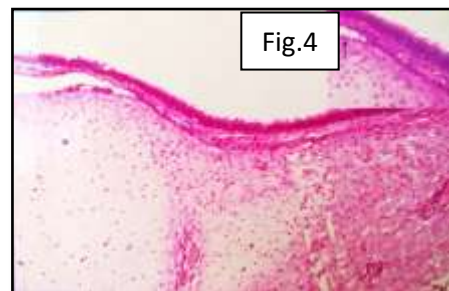
Congenital lobar emphysema (CLE) is the over distention of pulmonary lobe as a result of obstruction of bronchus and is a very rare condition. CLE presents in 1st week of life in about 50% of cases and in first 6 months in over 88% of cases.^[22] Two cases in our study presented in first month while one case presented in fourth month. Ekkelkamp S et al and David et al concluded that the disease is generally unilateral and on left side with involvement of upper lobe in 95% of cases,^[23,24]

this is similar to observations in present study. Some authors have found associated anomalies in cases of CLE in 40% of cases and 70% of these are cardiovascular.^[25] Out of three cases in our study one case had hypoplasia of right lung, right ventricular hypertrophy and dilatation. The exact cause of CLE is not known but cartilage abnormalities of the bronchial wall have been described other than bronchial obstruction.^[26,24] In all three cases the bronchus supplying the affected lobe showed presence of cartilage.(Figure-3)



Pneumatoceles are thin walled gas filled cysts developing commonly after consolidation of the lung, the incidence of which ranges from 2-3% in children.^[3] Usually pneumatoceles are multiple, both of our cases had single cyst in the lung which is in concordance with other studies^[3].

Bronchogenic cyst is a congenital lesion. It is a discrete extrapulmonary mass filled with fluid which has no communication with the bronchus. Ribet and colleagues reported that 70.8% of children were symptomatic, since 75% of these cysts were located around the carina (in the mediastinum), to which they concluded to be the most common location.^[27]



In one of our case, the cyst was located in the posterior mediastinum on right side and patient had fever and cough since 4-5 months. Other patient had a cyst on anterior chest wall since birth which was forming discharging sinus. The wall of bronchogenic cyst contains cartilage and serous glands.^[27-29] In our study cartilage was

present in one case while glands and squamous metaplasia was present in other case (Figure-4). Simple lung cyst is a group of small cysts lined by flattened endothelial like cells.^[30] In our study we had one case of simple lung cyst. The radiological diagnosis was given different in the same case.

Conclusion

Cystic lung diseases in children are uncommon group of disorders which may be caused by a variety of congenital and acquired processes. Of these congenital cystic diseases are extremely rare but life-threatening. Bronchiectasis and hydatid cysts were the common acquired cystic lesions while congenital lobar emphysema and congenital cystic adenomatoid malformation were the common congenital lesions. The etiology, treatment and prognosis differ among these cases and thus a proper diagnosis should be made. High-resolution CT scan has added immensely for diagnosis of such cystic lesions. Detailed attention should be paid to clinical features, location, distribution, gross morphology, associated radiological findings and associated anomalies along with lining of the cyst for their accurate diagnosis.

Conflict of Interest: None declared

Source of Support: Nil

Ethical Permission: Obtained

References

1. H. Spencer. Lung cyst and sequestration. Pathology of the lung, 4th edition, Vol 1, Pergamon press. P 86-108.
2. Kenneth J. W, Judson G. R, James A. O. Pediatric surgery. Fourth edition. Year book medical publishers, INC. p 645-646.
3. Denise Serebrisky, Arthur B Atlas, Debra Boyer Pneumatocele. <http://emedicine.medscape.com/article/1003289-overview>.
4. H. Spencer. Hydatid disease of the lung. Pathology of the lung, 4th edition, Vol 1, Pergamon press. P 394-400.
5. H. Spencer. Bronchiectasis. Pathology of the lung. 4th edition, Vol 1, Pergamon press. P 147-165.
6. Field CE. Bronchiectasis in childhood. I. Clinical survey of 160 cases. Arch Dis Child. 1949;4:21-46.
7. Mary E Cataletto, Girish D Sharma. Bronchogenic Cyst <http://emedicine.medscape.com/article/1005440-overview>
8. Kevin K. R, Christopher K. B, Stephen R. C, Katrine H, Arlet G. K, et al: The Unpredictable Character of Congenital Cystic Lung Lesions. Journal of Pediatric Surgery, 2000;35(5):801-805.
9. Frederique S, Jean-Luc M, Alexander B, Sophie E and Yann R, et al: Management of Asymptomatic Neonatal Cystic Adenomatoid Malformations. Journal of Pediatric Surgery, 2003;38(4):548-552.
10. Mary J. B, Donald L. S, Barry R. C, et al: Spontaneous Resolution of a Cystic Lung Mass: A Case Report. Journal of Pediatric Surgery, 2002;37(6):916-918.
11. H.Noriaki U, Shinkichi K, Toshio S, Masafumi K, Hiroomi O, et al: Outcome Predictors for Infants With Cystic Lung Disease. Journal of Pediatric Surgery, 2004;39(4):603-606.
12. Julie A. M, Jane E. C, Jacob C. L, et al: Congenital Cystic Adenomatoid Malformation in the Fetus: Natural History and Predictors of Outcome. Journal of Pediatric Surgery, vol 31, No 6 (June), 1996: P 805-808.
13. Davenport M, Warne S.A, Cacciaguerra S, Patel S, Greenough A. et al: Current Outcome of Antenally Diagnosed Cystic Lung Diseases. Journal of Pediatric Surgery, 2004;39(4):549-556.
14. Nemir R L. Bronchiectasis. Kendige L, Chernick V eds. Disorders of respiratory tract in children. London: W B Saunders Co. 1983; 538-550.
15. William M. Thurlbeck and Andrew M. churg. Pathology of the lung. 2nd edition, 1995, Thieme medical publishers, Inc. New York. P 804-808.
16. Nemir R L. Hydatid disease of the lung (Pulmonary hydatidosis). Kendige L, Chernick V eds. Disorders of respiratory tract in children. London: W B Saunders Co. 1983; 1050-1056.
17. Aydin A, Yurdakal Y, Coskun I and Argun S. Pulmonary Hydatid Disease: Report of 100 Patients. The Annals of Thoracic Surgery. 1977;23(2):145-151.
18. Ayten K. C, Ekber S, Hadi A and Sinasi Y. Surgical Treatment of Pulmonary Hydatid Cysts in children. Journal of Pediatric Surgery, 2001;36(6):917-920.
19. Muharrem C, Canan S, Murat K and Bulent A. Surgical Treatment of Pulmonary Hydatid Disease in Children: Report of 122 Cases. Journal of Pediatric Surgery, 2002;35(12):1710-1713.
20. J. Thomas Stocker and Louis P. Dehner. Congenital cystic adenomatoid malformation. Pediatric pathology. Second edition. P 466-473.
21. Kuojen T, Samuel H, Lan Vu, Diana L. F and Hanmin L, et al: Resolution of Hydrops Fetalis in Congenital Cystic Adenomatoid Malformation After Prenatal Steroid Therapy. Journal of Pediatric Surgery, 2003;38(3):508-510.
22. Joyaube C, Mona B, Dickens St-Vil and Maria Di L et al: Unilobar Congenital Pulmonary Lymphangiectasis Mimicking Congenital Lobar Emphysema: An Underestimated Presentation. Journal of Pediatric Surgery, 2004;39(5):677-680.
23. Ekkelkamp S and Vos A et al: Successful Surgical Treatment of Newborn with Bilateral Congenital Lobar Emphysema. Journal of Pediatric Surgery, 1987;22(11):1001-1002.
24. David T, Samuel S, McBride J and Lynne R et al: Polyalveolar lobe: Anatomic and Physiologic Parameters and Their Relationship to Congenital Lobar Emphysema. Journal of Pediatric Surgery, 1980;15(6):931-937.
25. Turkan T E, Nermin G and Ertan O et al: Infantile Lobar Emphysema and Tracheal Bronchus in a Patient with Congenital Heart Disease. Journal of Pediatric Surgery, 2001;36(10):1596-1598.
26. Ibrahim K, Mehmet E S and Buyukpamukcu N et al: Congenital Lobar Emphysema: Diagnostic and Therapeutic Considerations. Journal of Pediatric Surgery, 1999;34(9):1347-1351.
27. Kerilyn K. N, Yara C. G and Robert C. S, et al: Bronchogenic Cysts and Esophageal Duplications: Common Origin and Treatment. Journal of Pediatric Surgery, 1997;32(10):1408-1413.
28. Harle C. C, Dearlove O, Walker R. W. M, Wright N, et al: A Bronchogenic Cyst in Infant Causing Tracheal Occlusion and Cardiac Arrest. Anaesthesia, 1999;54:262-265.
29. Christopher J. W, Harry T and Peter C, et al: Bronchogenic Cyst: A Cause of Pulmonary Artery Obstruction and Breathlessness. Ann Throat Surg, 1993;55:1254-1255.
30. Soosay G.N, Baudouin S.V, Hanson P.J.V, Fontana G, Jagjivan A, Goldstraw P, Collins J.V. and Sheppard M.N. Symptomatic cysts in otherwise normal lungs of children and adults. Histopathology, 1992;20(6):517-522.