

Study of Lip Patterns in Vidarbha Region of Maharashtra

Tabhane MK¹, KSheersagar DD², Wakode NS³, Rahule AS⁴, Tambe SV⁵

1: Associate Professor, Anatomy NKPS Institute of Medical sciences Hingna Nagpur

2: Professor & Head, Anatomy NKPS Institute of Medical sciences Hingna Nagpur

3: Associate Professor, Anatomy, AIIMS Bhubneshwar (Orissa)

4: Professor & Head, Anatomy, Government Medical College, Rajnandgaon

5: Associate Professor, Anatomy, Government Medical College, Akola

Abstract

Introduction: The pattern of wrinkles on the lips has individual characteristics as fingerprints. Cheiloscopy (quiloscopy) can be defined as a method of identification of a person based on characteristics arrangement of lines appearing on the red part of a lip. It is a forensic investigation technique that deals with identification of human based on lip traces. Present study is aims to find out lip pattern common in Vidarbha region. **Materials & Methods:** Lip prints of 222 randomly selected subjects were obtained using dark coloured lipsticks, and cellophane tape. Lip prints were analysed using magnifying lens and classified according to the Yasuo Tsuchihashi classification. **Result & Conclusion:** It was found that type II lip print is the most common type in Vidarbha region in both the male and female. Each lip print is different in different compartment.

Keywords: Cheiloscopy, lip print, quiloscopy

Address for correspondence: Dr. Tabhane M.K. Associate Professor, Anatomy NKPS Institute of Medical Sciences, Hingna, Nagpur. E-mail: rahuleanil@yahoo.co.in +919422255177

Received on: 24/01/2017 Revised: 27/01/2017 Accepted : 31/01/2017

Introduction

Lips are two fleshy folds surrounding the oral orifice. The lip has many elevations and depressions forming a characteristic pattern called lip print Cheiloscopy (quiloscopy) can be defined as a method of identification of a person based on characteristic arrangement of lines appearing on the red part of lips or as a science dealing with lines appearing on the red part of lips. It is used for personal identification since lip prints are unique for individuals and do not change during the life of a person⁽¹⁻⁶⁾.

It is possible to identify the lip patterns as early as the sixth week of the foetal stage⁽²⁾. Since then, the lip print pattern remains permanent, resisting climatic change, minor traumas, inflammation, and afflictions such as herpetic lesions^(1,2). The oily and moist secretions from sebaceous and salivary glands located at the vermilion border and subsequent moisturization from the tongue enables the formation of a latent lip print⁽²⁾.

Identification plays a very important role in any crime investigation^(7,8,9,10). Fingerprint system was first used in India in 1858 by Sir William Herschel⁽⁵⁾. Lip prints are considered unique to an individual and analogous to fingerprints⁽⁵⁾. In the early 1950s Le Moyne Snyder a forensic expert from California introduced a concept that utilized the wrinkles and grooves of the lips as a method of identification. Many researchers observed these in 1960s and 70s⁽³⁾. The biological phenomenon of systems of furrows on the red part of the human lips was first noted and described by anthropologist Fischer^(3,4). However until 1930, anthropology merely mentioned the existence of furrows without suggesting a practical use for the phenomena. Edmond Locard was one of the France's greatest criminologists who first recommended the use of lip prints in personal identification and criminalization. Suzuki and Tsuchihashi made some other important observations too^(3,7). LeMoyne Snyder in his book Homicide Investigation, written as early as

1950, mentions the possible use of lip prints in the identification of individuals⁽⁴⁾.

Present study is aims to find out lip pattern common in Vidarbha region, whether there are different types of lip prints in different part of lips, which type of lip print is common in each compartment of upper and lower lip and which type of print is commonest among the male or female.

Materials & Methods

The present study has been conducted on randomly selected 222 subjects. Careful examination was done during the selection of subjects to eliminate those individuals who had developmental, morphological and pathological deformities of lips. Subjects having normal structure and functions of lips has been included in our study.

Determination of lip print pattern

In order to determine the lip print pattern, each individual's

Lips were divided into six compartments, i.e. three compartments on each lip [Figure 1].

The classification system by Tsuchihashi^(3, 11) was used. According to this classification [Figure- 2], lip print patterns are divided using a magnifying lens as follows:

Type I: Clear cut vertical grooves that run across the entire lips

Type I': Similar to Type I, but do not cover the entire lip

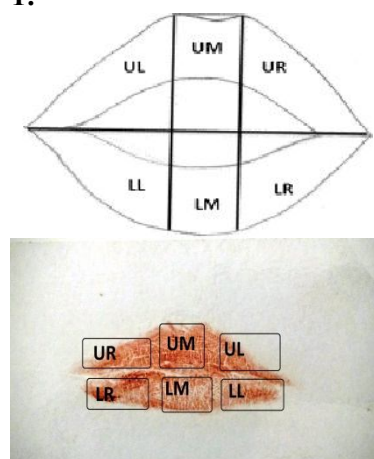
Type II: Branched grooves

Type III: Intersected grooves

Type IV: Reticular grooves

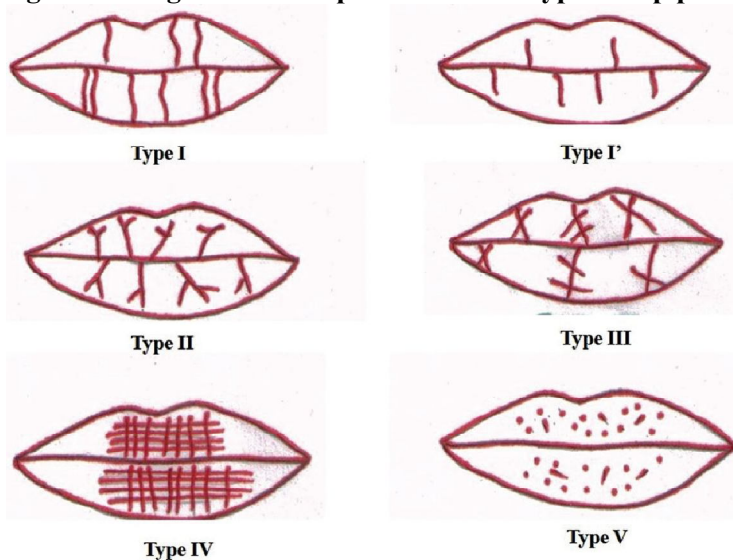
Type V: Grooves do not fall into any of the types, i.e. Type I-IV, and cannot be differentiated morphologically.

Figure- 1:



Where; UR, upper right; UM, upper middle; UL, upper left; LR, lower right; LM, lower middle; LL, lower left

Figure 2: Diagrammatic representation of types of lip prints



Recordings of lip prints:

Dark coloured, non persistent, non glossy, non metallic with less moisture and oil content lipstics were used to develop clear lip prints on white paper, transparent cellophane tape, and

tissue paper were used in this process. Cleaning of lips was done by using tissue paper. After obtaining the consent, a thin layer of lipstick was applied evenly on the vermilion border. The individuals were asked to rub both the lips to

spread the lipstick. After about 2 min, once the lipstick had dried, the glued portion of the cellophane tape strip was placed and the individual was asked to make a lip impression in the normal rest position of the lips by dabbing it in the centre first and then pressing it uniformly toward the corners of the lips. The cellophane strip was then stuck to the executive bond paper for permanent record purpose and then visualized by magnifying lens. The lip prints were coded based on the name and the sex of the individuals. It was analysed using magnifying lens since the print remain secured under the tape for more than 2 months. ^(2,4)

For sex determination using lip prints

For assessing the sex of the individuals using their lip prints, the description given by Sharma et al^[4,11,] was used.

According to this description:

Type I, I': Pattern dominant in female

Type II: Pattern dominant in female

Type III: Pattern present in male

Type IV: Male

Type V: Male (varied pattern).

Same patterns in all quadrants – Female

Examination of lip prints was be done by the method followed by El Domaity M A et al. ⁽¹⁰⁾

Results

The examination of lip print patterns revealed that no two lip prints matched with each other, thus establishing the uniqueness of the lip prints. We have examined total of 444 lips in six different compartments, among these 152 were females and 70 were males. The most predominant pattern in the entire study population was Type II (132.43%) **Figure- 3**

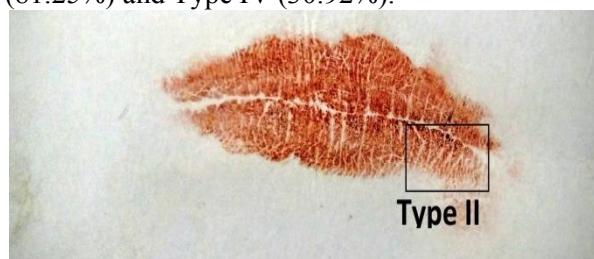
Type IV (30.40%) **Figure 5,**

Type III 23.42%) **Figure 6**

Type I' (20.72%) **Figure 7 and**

Type V (3.82%) **Figure 8**

In females Type II (135.52%) lip pattern was most commonly found followed by Type I (81.25%) and Type IV (30.92%).



This was followed, in order, by Type I (86.03%)

Figure- 4

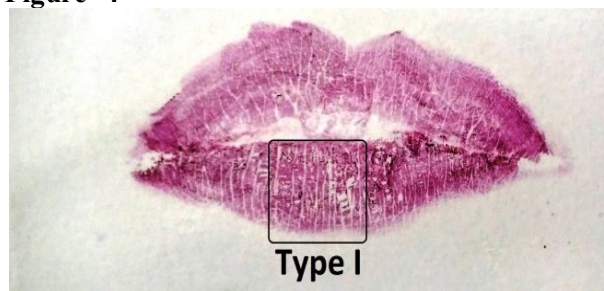


Figure- 5

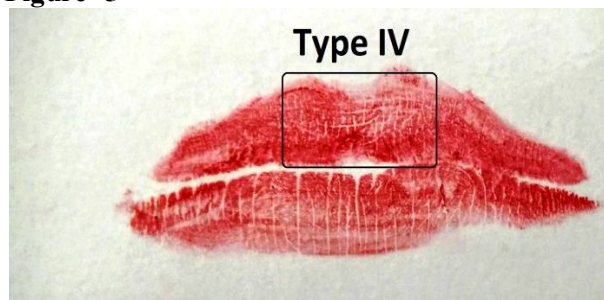
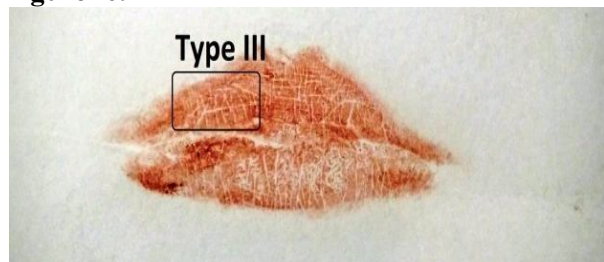


Figure- 6.



In males, Type II (125.71%) lip pattern was predominant, followed by Type I (96.42%) and Type IV (29.28%). So the most common lip pattern for both female and male is Type II.

In male for upper lip the most common pattern is Type II (118.57%) and for lower lip is Type I(110%).In female for upper lip the most common pattern is Type II(81.04%) and for lower lip is Type II (104.50%). In UR compartment Type II lip prints is most common in both male and female.

Figure- 7

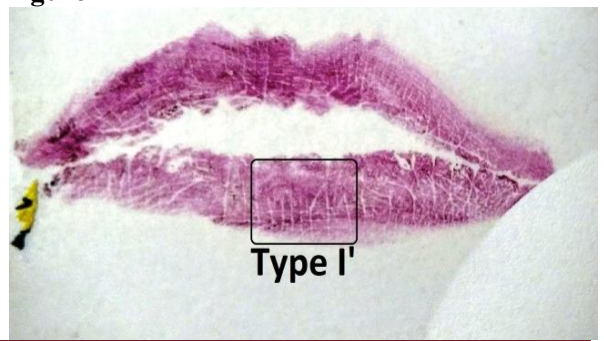
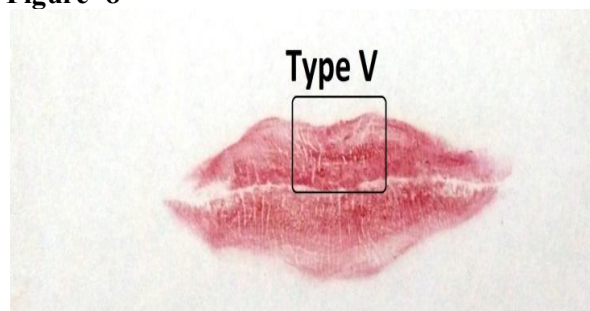


Figure- 8



In UM compartment Type IV lip prints is most common in both male and female.
 In UL compartment Type II lip prints is most common in both male and female.
 In LR compartment Type II lip prints is most common in both male and female.
 In LM compartment Type I lip prints is most common in both male and female.
 In LL compartment Type II lip prints is most common in both male and female.

Table- 1: Frequency of lip print Types in different compartments of lip

Compartment	Sex	Frequency of lip print Types					
		I	I'	II	III	IV	V
UR	M	22	4	30	7	3	1
	F	25	12	83	17	9	2
UM	M	22	8	10	5	25	-
	F	47	21	15	12	53	2
UL	M	14	4	37	8	3	3
	F	29	9	82	17	8	3
LR	M	17	2	40	7	1	1
	F	26	5	100	12	10	-
LM	M	46	8	12	-	4	4
	F	91	15	32	3	10	-
LL	M	14	1	41	5	5	2
	F	29	3	100	11	4	3

Note: UR-Upper right compartment, UM- Upper middle compartment , , UL- Upper left compartment , , LR- Lower right compartment , , LM- Lower middle compartment ,, LL- Lower left compartment, M- male, F-female

Table- 2: Frequency of lip print Types in both upper and lower lips

Compartment	Sex	Frequency of lip print Types(%)					
		I	I'	II	III	IV	V
UL	M	58(82.85%)	16(22.85%)	83(118.57%)	20(28.57%)	31(44.28%)	4(5.71%)
	F	101(66.44%)	42(27.63%)	180(118.42%)	46(30.26%)	70(46.05%)	7(4.60%)
LL	M	77(110%)	11(15.71%)	63(90%)	12(17.14%)	10(14.28%)	3(4.28%)
	F	146(96.05%)	23(15.13%)	232(152.63%)	26(17.10%)	24(15.78%)	3(1.97%)

Note: UL- Upper lips, LL- Lower lips, M- Male, F- Female

Table- 3: Type of Lip prints

Type of lip prints	Male(n=140)	Female (n=304)	Total(n=444)
I	135(96.42%)	247(81.25%)	382(86.03%)
I'	27(18.28%)	65(21.38%)	92(20.72%)
II	146(125.71%)	412(135.52%)	588(132.43%)
III	32(22.85%)	72(23.68%)	104(23.42%)
IV	41(29.28%)	94(30.92%)	135(30.40%)
V	7(5%)	10(3.28%)	17(3.82%)

Discussion

Human identification is one of the most challenging subjects that man has been confronted with. Identification of an individual is a pre-requisite for certification of death and for personal, social and legal reasons. Lip prints can be instrumental in identifying a person

positively ^(9,12). The edges of the lips have sebaceous glands with sweat glands in between, therefore, secretions of oil and moisture enable development of 'latent' or persistent lip prints, analogous to finger prints. ^(9,13)

In this study it is observed that the maximum number of male subjects have Type II lip prints 146(125.71%) and the minimum number of

subjects have Type V lip prints 7(5%). It is observed that the maximum number of female subjects have Type II lip prints 412(135.52%) and the minimum number of subjects are having Type V lip prints 10(3.28%) (Fig-7). However, this study reveals that Type III may not be commonest in both males and females as it was reported by Tsuchihashi. ⁽¹⁴⁾ It was also observed that no two persons had similar lip prints, either the same type or different types. It was further noticed that not even a single person had one

particular type of lip print in the upper lip or lower or in both. Thus the statement of Tsuchihashi ⁽¹⁴⁾ is true and can be justified in stating that each of the 222 subjects has his own or her own lip print.

In addition, every compartment in each individual did not have only one pattern, but appeared to have a mixture of different patterns. These findings were consistent with previous studies. ^(9,10)

Table 4. Study of lip print pattern by different authors in India. ^(9,10)

Region of Study	Lip pattern	Year of study
Mumbai, Maharashtra Aurangabad, Maharashtra	Predominant Pattern: In Males: Type III In Females: Type I Predominant Pattern: Males and Females: Type III	2000 2008
Meerut, Uttar Pradesh Dehradun, Uttarakhand	Predominant Pattern: In Males: Type IV In Females: Type Predominant Pattern: Males and Females: Type II [60.50% / 66.83%]	2009 2009
Bangalore, Karnataka Kanpur, Uttar Pradesh	Predominant Pattern: In Males: Type IV In Females: Type I Predominant Pattern: Males and Females: Type III [39.5% & 36.5%]	2009 2009
Udaipur	Predominant Pattern: In Males: Type I In Females: Type II	2010
Amritsar, Punjab	Predominant Pattern: In Males: Type III In Females: Type I	2011
Raichur, Karnataka	Predominant Pattern Males and Females: Type IV	2011
Bangalore, Karnataka	Predominant Pattern: Males and Females: Type II	2011
Lucknow, Uttar Pradesh	Predominant Pattern: In Males: Type II In Females: Type III	2011
Jaipur, Rajasthan	Predominant Pattern: Males and Females: Type III	2011
Modi Nagar, Uttar Pradesh	Predominant Pattern: In Males: Type IV In Females: Type I	2011
Delhi & Haryana	Predominant Pattern: In Males: Type III In Females: Type Y	2012
Punjab	Predominant Pattern: Males and Females: Type I	2012
Pondicherry	Predominant Pattern: In Males: Type III In Females: Type II	2012
Lucknow, Uttar Pradesh	Predominant Pattern: Males and Females: Type II [36.3% / 35.5%]	2013
Manipal, Karnataka	Predominant Pattern: In Females: Type IV [33.3%]	2013
Rohtak, Haryana	Predominant Pattern: In Males: Type III [45%] In Females:	2014
Rajnandgaon, Chhattisgarh	Type II [35%] Predominant Pattern: In Males: Type III Females: Type I	2014
Raipur, Chhattisgarh	Predominant Pattern: In Males and Females: Type I	2014
Nagpur, Maharashtra	Predominant Pattern: In Males and Females: Type II	Present study

It can be said that Type II lip print is predominant in both male and female in our study. This type of pattern was also found in previous three Indian studies of Dehradun, Uttarakhand, 2009, Lucknow, Uttar Pradesh, 2011, and Lucknow, Uttar Pradesh, 2013⁽¹⁵⁾

Therefore, it can be said that lip prints are also capable for individual identification in criminal investigation like fingerprints. As number of samples are small in our study for determining the discrimination power of lip prints in identifying the geographical affiliation with accuracy. In future, studies on more number of samples from different geographical regions and

ethnic races will help to determine the geographical origin and probable race of questioned lip prints. Thus, it can be said that lip prints do have potential for use as corroboratory evidence in criminal investigations.

Lip prints are unique for every person and show differences according to race and the ethnic origins of a person. In this study no two lip print patterns matched each other thus establishing the uniqueness of lip prints. It was found that type II lip print was the predominant pattern in both sex. The researchers did not observe any statistically significant difference between male and female in individual lip print types. Lip prints appear different in different compartments of lips.

Though emerging as a promising tool, lip print recording is a tedious task which is technique-sensitive. Lip print is found unique for each individual. No two individuals or group of individuals have similar lip print. Lip prints appear different in different compartments of lips.

Conclusion

It can be concluded that Type II lip print is predominant in Vidarbha region of Maharashtra and each individual has unique lip print. Each compartment of lip has unique pattern of print and male and female has a common pattern of Type II dominance.

Conflict of Interest: None declared

Source of Support: Nil

Ethical Permission: Obtained

References

1. Neethu Telagi, Ahmed Mujib, BR Spoorthi, and Rashmi Naik. Cheiloscopy and its patterns in comparison with ABO blood groups. *J Forensic Dent Sci.*2011 Jul-Dec; 3(2):77-80
2. Yogesh Vats, Jasmine Kaur Dhall, and AK Kapoor. Gender variation in morphological patterns of lip prints among some north Indian population. *J Forensic Dent Sci.*2012 Jan-Jun; 4(1):19-23.
3. T.N. Uma Maheswari & N. Gnanasundaram. Role of Lip prints in Personal Identification and criminalization. *Anil Aggarwal's Internet Journal of Forensic Medicine and Toxicology*,2011;12(1): 21.
4. Preeti Sharma, Susmita Saxena, Vanita Rathod. Cheiloscopy: The study of lip prints in sex identification. *J Forensic Dent Sci* , 2009;1(1):24-7.
5. Rachana V Prabhu, Ajit D Dinkar, Vishnudas Dinesh Prabhu, and Prasanna Kumar Rao. Cheiloscopy: Revisited. *J Forensic Dent Sci.*2012 Jan-Jun; 4(1):47-52.
6. Sharma P, Saxena S, Rathod V. Comparative reliability of Cheiloscopy and palatoscopy in human identification. *Indian J Dent Res* 2009;20(4):453-7.
7. Augustine J, Barpande SR, Tupkari JV. Cheiloscopy as an adjunct to forensic identification: A study of 600 individuals. *J Forensic Odontostomatol* 2008 1;26(2):44-52.
8. Patel, S., Ish Paul, Madhusudan, A.S., Ramesh, G. And Sowmya, G.V. 2010. A study of lip prints in relation to gender, family and blood group. *International Journal of Oral & Maxillofacial Pathology*, 1(1): 4-7.
9. K. Randhawa, R. S. Narang, P. C. Arora. Study of the effect of age changes on lip print pattern and its reliability in sex determination. *J Forensic Odontostomatol* 2011;29(2):45-51).
10. El Domiaty MA, Al-Gaidi SA, Elayat AA, Safwat MD, Galal SA. Morphological patterns of lip prints in Saudi Arabia at Almadinah Almonawarah province. *Forensic Sci Int J*, 2010; 200(1-3): 179.e1-179.e9.
11. Prabhu RV, Dinkar A, Prabhu V. A study of Lip prints pattern in Goan dental students-A digital approach. *J Forensic Leg Med.* 2012 Oct;19(7):390-5.
12. Abhishek Karn, Rachana Karna, Prava Bajgain, Birendra Kumar Mandal. Morphological patterns of lip prints in relation to gender in a defined cohort. *Eur J Forensic Sci.* 2015;2(1):14- 17.
13. Alvarez M, Miquel M, Castello A, Verdu FA. Persistent lipsticks and their lip prints; new hidden evidence at the crime scene. *Forensic Sci Int.* 2000;112:41-7
14. Tsuchihashi, Y. Studies on personal identification by means of lip prints. *Forensic Science Int.*1974; 3: 233-48
15. Aditya Kar and Mitashree Mitra, Moumita Sinha. Extent of lip print pattern variation among people of Raipur, Chhattisgarh, India. *International Journal of Current Research.*2016;8(4):28965-28970.