

CASE REPORT

An Uncommon Case of Pyogenic Granuloma- Buccal Mucosa of Male

Tarona Azem Subba¹, Amitha Ramesh³, Biju Thomas³

1. II MDS Periodontics, AB Shetty Memorial Institute of Dental Sciences, Nitte University, Mangalore

2. Professor, Dept. of Periodontics, AB Shetty Memorial Institute of Dental Sciences, Nitte University, Mangalore

3. Professor & HOD, Dept. of Periodontics, AB Shetty Memorial Institute Of Dental Sciences, Nitte University, Mangalore

Abstract

Pyogenic granuloma, called so even though it is not associated with pus or a granuloma, is a benign, exuberant tissue growth which may present because of local irritation or trauma. The lesion may be clinically presenting as a single nodule, it may be pedunculated or sessile and its surface may be smooth or with lobules. In the oral cavity it is seen mainly in the gingiva but in some isolated cases it may present extragingly. Here, we report a rare case report of pyogenic granuloma in the buccal mucosa of a 32 year old man which is not only a rare location for this lesion but also did not exhibit bleeding on probing on clinical examination, which is commonly seen with this lesion.

Keywords: pyogenic granuloma, excision, buccal mucosa

Address for correspondence: Dr. Tarona Azem Subba. 4th Floor, Dept. Of Periodontics, A B Shetty Memorial Institute Of Dental Sciences, Nitte University, Deralakatte, Mangalore- 575018. Mobile No.- 9148735548 Email- taronaasubba@gmail.com

Received on: 01/05/2017 Revised: 07/05/2017 Accepted : 08/06/2017

Introduction

Kelley and Bernard regard pyogenic granuloma as a “Benign, Acquired, Vascular, Neoplasm”. Clinically it may appear as a tumor like growth, but it is considered non-neoplastic.¹ Pyogenic granuloma was first reported in the English literature by Hullihen in 1844 and the term was coined by Hartzell in 1904. The term pyogenic granuloma is a misnomer since it is not associated with pus nor is a granuloma represented histologically. The term “hemangiomasgranuloma” was proposed by Angelopoulos and it expressed accurately the histopathologic picture (hemangioma like) and the inflammatory nature (granuloma) of the lesion. Then Cawson et al. suggested an alternative term as granuloma telangiectaticum since the blood vessels were so numerous in oral pyogenic granuloma.²

According to Vilmann et al., the most common anatomical location is the gingiva, more specifically marginal gingiva is more commonly involved in comparison to other parts of the

gingiva. Other less frequently affected oral sites are the lower lip, tongue, buccal mucosa, upper lip and palate.³ Regezi et al attributed the precipitating factors to local irritants such as calculus, foreign material in the gingiva and poor oral hygiene. Jafarzadeh et al said that pyogenic granuloma may occur in all age groups, though it is predominantly seen in young females in the second decade of life because of the hormonal changes in this period. Neville et al clinically described these lesions as presenting as a localized elevated lump with a sessile or pedunculated appearance. The surface may be smooth or lobulated, and the color may range from pink to red or purple.⁴ Diagnosis of the lesion is mainly by histopathological examination and treatment of pyogenic granuloma consists of surgical excision along with elimination of irritating local factors where the recurrence rates may vary from 0% to 16%.⁵

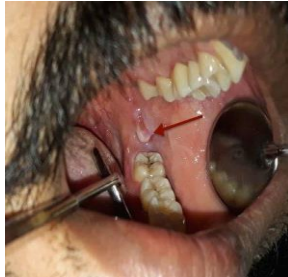Case Report

A 30 year old male patient reported to the Department of Periodontology with a chief

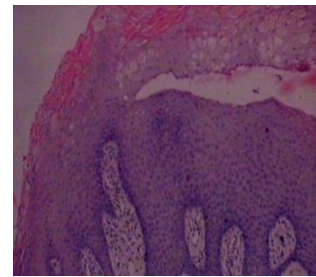
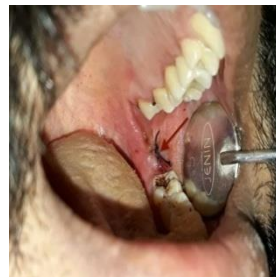complaint of stains since 3 months. On general oral examination a lesion was seen on the buccal mucosa 5-6mm above the occlusal plane in relation to 37,38. The lesion was first noticed by

patient 3 months ago, it was occasionally associated with mild pain and discomfort on chewing.

Pre-operative lesion



Post-operative picture



The patient had no relevant dental and medical history. Extraoral examination did not reveal any facial asymmetry. Intraoral examination revealed a roughly rounded exophytic pedunculated lesion present in the buccal mucosa in relation to 37 & 38, measuring about 0.5 x 0.5 cms. The lesion was pinkish red in color, soft and smooth in consistency. Spontaneous bleeding was not present. The lesion was isolated to the buccal surface.

The oral hygiene status was fair. Blood investigations showed normal levels. Differential diagnosis of Traumatic fibroma, irritational granuloma and pyogenic granuloma was made. The irritational factors (Plaque and Calculus) were eliminated by scaling and root planning.

Prophylactic excision of the lesion using scalpel was decided and the patient was educated about the treatment plan. Informed consent was obtained. Surgical excision of the entire lesion was carried out under local anesthesia using a scalpel and blade. Profuse bleeding was experienced during excision. It was controlled by pressure pack and suturing of the area. The excised tissue was sent to the Department of Oral Pathology for histological examination. The patient was recalled after 1 week for checkup and suture removal.

The histopathologic examination of H and E stain revealed parakeratinized stratified squamous epithelium with underlying connective tissue stroma. Fibrocellular connective tissue showed numerous endothelium lined vascular channels, bundles of collagen fibres and chronic inflammatory cell infiltrate and extravasated RBCs. These findings were suggestive of pyogenic granuloma.

Discussion

Hullihen's description in 1844 was most likely the first PG reported in the English literature. Then it was described in 1897 by Poncet and Dor (called botryomycosis hominis). Pyogenic granuloma has been referred to by a variety of other names such as granuloma pediculatum benignum, benign vascular tumor, pregnancy tumor, vascular epulis, Crocker and Hartzell's disease. It was given its present name by Crocker in 1903. However, some researchers believe that Hartzell in 1904 introduced the term "pyogenic granuloma"¹

Lawoyin et al said that pyogenic granuloma may occur at all ages but is predominantly seen in the second decade of life in young adult females, possibly because of the vascular effects of female hormones. Zafarzadeh et al showed that the gingiva is the most commonly affected site followed by the buccal mucosa, tongue and lips.²

This case report shows an uncommon case of a pyogenic granuloma which was managed by surgical excision. The lesion may be clinically presenting as single nodule, it may be pedunculated or sessile and its surface may be smooth or with lobules. The size of the lesion may vary from a few millimeters to several centimetres.² In this case it was rounded, pedunculated and 0.5 x 0.5 cm.

Here, the treatment of choice was conservative excisional biopsy of the entire lesion from its base to reduce the frequency of recurrence and to rule out a more serious pathology by histopathological diagnosis, accompanied by

prophylactic and postoperative antibiotic and analgesic therapy with regular follow-up.

A careful management of the lesion also helps in preventing the recurrence of this benign lesion. ²Bhaskar and Jacoway has reported recurrence rate of 15.8% after conservative excision. Sapp et al. stated that oral PGs have a relatively high rate of recurrence after simple excision but Lawoyin et al. observed no recurrence in cases treated by the same method. Al-Khateeb et al. (2003) observed a recurrence rate of 5.8% in his study.¹

Reichart et al said that surgical excision was the treatment of choice. If the lesion is small, painless and free of bleeding, clinical observation and follow up are advised. Other treatment modalities include laser surgery, electro dessication. Injection of absolute ethanol, sodium tetradecyl sulfate (sclerotherapy) and corticosteroids have also been tried with successful results in cases with recurrent lesions but these modalities have not been evaluated completely.^{7,8}

Surgical excision was done using no.15 blade under local anesthesia. The difficulty encountered during excision was profuse bleeding which had to be controlled with pressure pack and suture. Healing appeared satisfactory and there was no recurrence of the lesion after a month of follow up.

Conclusion

Pyogenic granuloma is a common tumor-like lesion in the oral cavity; occurring in females more than males and 80% cases are seen in the gingiva. This is an uncommon case of a male patient with pyogenic granuloma in the buccal mucosa. Patients may detect the lesion and fear of a more serious pathology, especially when it occurs more commonly on anterior gingiva. Therefore, familiarity with the clinical appearance, etiology and the various treatment modalities so as to best manage the patient and treat the lesion is advisable.

Acknowledgement

The Authors would like to acknowledge the Department of Oral Pathology, ABSMIDS, Nitte University for their work with the specimen.

Conflict of Interest: None declared

Source of Support: Nil

Ethical Permission: Obtained

References

1. Kamal R, Dahiya P, Puri A. Oral pyogenic granuloma: Various concepts of etiopathogenesis. *Journal of Oral and Maxillofacial Pathology*. 2012;16(1):79.
2. Kumar Verma P. Erratum - "Pyogenic Granuloma - Hyperplastic Lesion of the Gingiva: Case Reports". *The Open Dentistry Journal*. 2012;6(1):188-188.
3. Assaf M. Oral Pyogenic Granuloma : A Literature Review and Case Report. *Smile Dental Journal*. 2014;9(4):18-21.
4. Neville B W, Damm D D, Allen C M, Bouquot J E. *Oral & maxillofacial pathology*. 2nded. Philadelphia: WB Saunders, 2002.
5. Zain R, Khoo S, Yeo J. (1995). Oral pyogenic granuloma clinical analysis of 304 cases. *Singapore Dent J*;20:8-10.
6. Rucha D, Yusuf C, Abdul M, Rohan T. Oral telangiectatic granuloma. *Univ Res J Dent* 2016;6:182-5.
7. Al-Khateeb T, Ababneh K. (2003). Oral pyogenic granuloma in Jordanians: a retrospective analysis of 108 cases. *J Oral Maxillofac Surg*;61:1285-88.
8. Jafarzadeh H, Sanatkhan M, Mohtasham N. Oral pyogenic granuloma: A review. *J Oral Sci*. 2006;48:167-75.