

CASE REPORT

Gingival Pyogenic Granuloma – Case Report

Akshara Mary Jacob¹, Supritha S. Pai², Nina Shenoy³, Amitha Ramesh⁴

1&2. Post graduate, Department of Periodontics, A.B. Shetty Memorial Institute of Dental Sciences, Nitte University, Deralakatte, Mangalore

3&4. Professor, Department of Periodontics, A.B. Shetty Memorial Institute of Dental Sciences, Nitte University, Deralakatte, Mangalore

Abstract

Pyogenic Granuloma is an inflammatory hyperplastic soft tissue lesion of the skin and mucous membrane predominantly seen in young females primarily due to the hormonal changes during this period, expressed as a change in oestrogen and progesterone levels. It could also be due to the exaggerated response to local factors, chronic trauma, immunosuppressant drugs and iatrogenic factors. Histopathological examination is required to confirm the diagnosis. Once diagnosed, the treatment consists of surgical excision extending down to periosteum and removal of the predisposing factors. This article reports the case of a 40 years old female patient with pyogenic granuloma which was surgically managed.

Keywords: Granuloma, lesion, pyogenic

Address for correspondence: Dr. Akshara Mary Jacob. Post Graduate, Department of Periodontics, A.B. Shetty Memorial Institute of Dental Sciences, Nitte University, Deralakatte, Mangalore 575018

Email: akshara.mary@gmail.com Contact no : 07259030134

Introduction

In 1904, Hartzell gave the term “pyogenic granuloma” or “granuloma pyogenicum”. Pyogenic Granuloma is an inflammatory hyperplastic soft tissue tumor of skin and mucous membrane. ⁽¹⁾ Pyogenic granuloma is a misnomer as it does not represent a true granuloma and is usually not associated with pus. ^(2,3)

Incidence and Prevalence

A study conducted by Bhaskar *et al*; concluded that oral pyogenic granuloma comprised of about 1.85% of all oral pathoses, excluding gingivitis and caries treated at the US Army Institute of Dental Research. Shamim *et al*; analyzed 244 gingival lesions and concluded that pyogenic granuloma was the most commonly occurring lesion among the non-neoplastic lesions, in the south Indian population. ⁽⁴⁾ As regulated by various studies, Pyogenic granuloma can occur at any age, predominately in second and third decade of life with a high incidence in female, caused due to the vascular effects of female hormones. A recent study reported it was most commonly seen in sixth decade of life with the average age

of 52 years. Pilchetal believed it to have a high predilection of occurrence in males less than 18 years of age, females of 18 to 39 years with no gender predilection among older patients. A predominance in females (1:1.5) was reported by Epirationosetal. ⁽⁵⁾

Aetiology and Clinical Features

Clinically, pyogenic granuloma usually appears as a sessile papule or single nodule with a smooth or lobulated surface. ⁽³⁾ It can occur in all the age groups ⁽⁶⁾, although it is mainly observed in the second decade of life. It is seen predominately in females due to hormonal changes during this period, ⁽³⁾ especially an increase in oestrogen and progesterone levels. Increase in oestrogen levels can result in increased manifestation of vascular endothelial growth factor (VEGF) and basic fibroblast growth factor (bFGF) in macrophages, which consequentially leads to the development of pyogenic granuloma. ^(1,7) Increase in progesterone levels acts as an immunosuppressant in the gingiva of pregnant women which results in a chronic tissue reaction that clinically presents as inflammation in an exaggerated form. ⁽⁶⁾ Other causative factors could be exaggerated response to local

factors, chronic trauma, immunosuppressant drugs and iatrogenic factors.^(3,8) History of trauma and poor maintenance of oral hygiene are also considered as precipitating factors in approximately one third of the lesions. Drugs such as cyclosporin may also have an important role in genesis of pyogenic granuloma.⁽⁵⁾ The colour can vary, from red, reddish purple to pink subject to the vascularity of the lesion.^(1,9,10) It most commonly appears in the gingiva, particularly in the anterior maxillary region, accounting for almost 75% of the cases.^(3,6) The other common sites of involvement are lips, tongue and buccal mucosa. These lesions mostly affect anterior areas than posterior areas and are frequently seen occurring on the facial aspect than lingual aspect. A study done by Vilmann *et al*; concluded that majority of these lesions were seen on marginal gingiva.⁽⁵⁾ This article describes a case of pyogenic granuloma diagnosed in a 40 years old female patient.

Case Report

A 40 years old female patient, reported to the Department of Periodontics, with the chief complaint of a swelling in the gums with respect to the lower front region since 3 years. She experienced slight pain on chewing food and was concerned regarding aesthetics. The patient noticed an increase in the size of the swelling during her pregnancy which did not regress after parturition.

Intraoral Examination

The lesion was pedunculated, reddish with slight ulceration due to interference with the bite, located at the attached gingiva between 43 and

44, measuring around 2.5 x 3cm. The lesion covered approximately 2/3rd of the crown, was firm and non-tender, with bleeding on probing. No mobility was detected in relation to the associated teeth and oral hygiene status was fair. Her medical history was non-contributory. Radiographically, no evidence of bone involvement was seen. Complete haematological investigations revealed no abnormalities.

Provisional Diagnosis

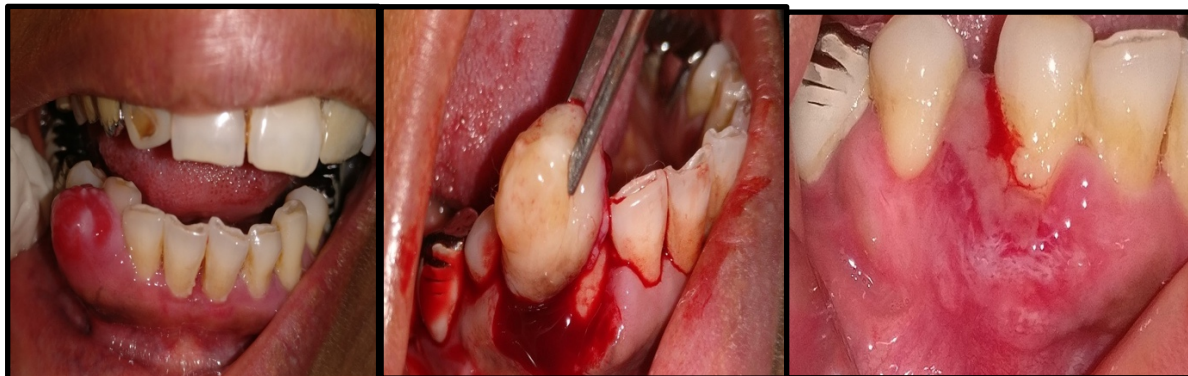
Based on the history given by the patient and the clinical findings, a provisional diagnosis of pyogenic granuloma with respect to 43, 44 regions were made.

Differential Diagnosis

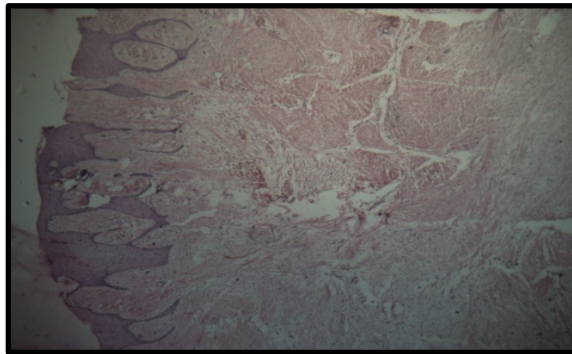
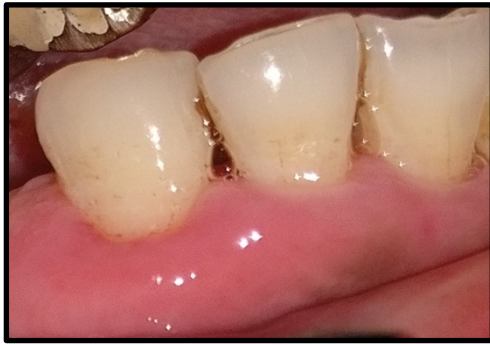Peripheral giant cell fibroma
Peripheral ossifying fibroma
Epulis

Treatment Plan

Scaling and root planning was performed on the first visit. Instructions for maintenance of oral hygiene were given and patient was prescribed 0.2% chlorhexidine gluconate mouthwash twice daily for 2 weeks for reduction of inflammation. Surgical management was done after 2 weeks on recall. Under local anesthesia, the lesion was excised surgically and the excised lesion was sent for histopathological analysis. Periodontal pack was placed at the surgical site and the patient was prescribed analgesics and antibiotics. For removal of pack and evaluation of healing, the patient was followed up after a week. Healing was uneventful. The patient was recalled after a month for follow up.



Pre-operative (lesion on 43, 44) Excision of the tissue 1 week after excisional biopsy



4 months after excisional biopsy Histopathological features

Histopathological Features

Histopathological examination revealed a hyperplastic, parakeratinized stratified squamous epithelium. The connective tissue was loose fibrillar and comprised of numerous proliferating capillaries, dense mixed inflammatory infiltrate, and extravasated red blood cells. The histopathological examination confirmed the clinical diagnosis of pyogenic granuloma.

Discussion

Pyogenic Granuloma is a soft tissue tumor which is believed to be non – neoplastic in nature. It occurs due to tissue trauma, irritation, hormonal changes or certain drugs. Cawson *et al*; has described it as “granuloma telangiectacticum” due to abundant blood vessels present in histological sections. They described two main types of pyogenic granulomas, the lobular capillary hemangioma (LCH) and the non-lobular capillary hemangioma (non-LCH).⁽⁶⁾

Clinically, the lesion appeared as a localized solitary nodule with a pedunculated base in the gingiva. The surface was slightly erythematous with slight ulceration and bleeding on probing. Bleeding after minor trauma and ulceration were also frequently noticed. The clinical findings were similar to the studies conducted by Martins-Filho *et al*; Gondivkar *et al*; Kejriwal *et al*; and Verma *et al*;^(3,7,11,12)

In this patient there was no radiographic evidence of bone loss. This is in accordance with a similar study done by Martins-Filho *et al*; and Kamal *et al*;^(4,11) However, contradictory to this, interdental alveolar crestal bone resorption was reported by Gondivkar *et al*; and a

extensive bone loss was reported by Verma *et al*.^(3,7)

Histologically, pyogenic granuloma consists of prominent vascular spaces lined with endothelium in a loosely arranged fibrillary matrix. All cases present with moderate to severe chronic inflammatory cell infiltrate, while polymorphonuclear leukocytes are observed in majority of the cases. Ulceration may be present in some granulomas. According Choukas & Toto, histological, pyogenic granulomas and endothelial sarcomas have similar histopathological features. After diagnosis, treatment includes elimination of the causative factors and surgical excision extending up to the periosteum⁽¹³⁾. In pregnant women, pyogenic granulomas are treated under local anesthesia after consulting with the primary care physician.⁽¹¹⁾

Pyogenic granuloma can be treated by several methods. Excisional biopsy is routinely carried out except when it creates marked deformity. Incisional biopsy would be carried out in such cases. Hence, the treatment modality varies depending on the extent of the lesion. When it is small, painless and free of bleeding, elimination of the causal factors is recommended along with surgical excision extending till the periosteum. However, complications of surgical excision include intraoperative bleeding and post operative infection which might cause delayed wound healing. Other treatment options like use of lasers, cryosurgery, injection of absolute ethanol, sclerotherapy and intra-lesional corticosteroids have been used.^(2, 14)

To overcome the disadvantages of surgical excision, different wavelengths of lasers have been used for various soft tissue procedures. Advantages of lasers include clean incision of

tissues, minimal or no soft tissue bleeding, pain and edema. It is considered as bloodless surgery as it improves visualization of surgical site by sealing the blood vessels. In areas concerning esthetics, it is a minimally invasive technique when compared to scalpel and cryosurgery. Various lasers that have been used to treat pyogenic granuloma include Nd:YAG laser, carbon dioxide laser, Er:YAG laser and the diode laser.^(14,16) Diode lasers are most commonly used in 3 wavelengths-810nm,940nm and 980nm in surgical treatments. However, most of the laser wavelengths are expensive and their machines are bulky,thus it may be expensive for conventional surgical excisions.⁽¹⁷⁾ Surgical excision is cost effective and is also a successful method in minimizing the recurrence of the lesion⁽³⁾ Hence, surgical excision continues to be the most conservative and frequently utilized method of excision for oral lesions.

Pyogenic granulomas have a recurrence rate of upto16%, especially when it is on the gingiva.⁽³⁾ Recurrence can occur due to incomplete elimination of the causative factors, incomplete excision or due to the presence of any factors that can cause re-injury of the area. Re excision becomes a necessity for such cases.

Conclusion

In this case report, the patient presented with a large gingival overgrowth in the lower anterior region. Clinical history and histopathological features confirmed the diagnosis of pyogenic granuloma, which occurs frequently in the gingiva. The lesion was excised and seemed to respond well to the treatment which was observed for a period of 6 months with no sign of recurrence. The patient is currently under observation and maintenance therapy.

Conflict of Interest: None declared

Source of Support: Nil

Ethical permission: Obtained

References

1. Gomes SR, Shakir QJ, Thaker PV, Tavadia J K. Pyogenic Granuloma of the gingiva: A misnomer? - A case report and review of literature. Journal of Indian Society of Periodontology 2013;17(4):514-19.
2. Alexander Leung KC, Barankin B, Hon KL. Pyogenic Granuloma. Pyogenic Granuloma. Clinics Mother Child Health 2014; e106
3. Verma PK, Srivastava R, Baranwal HC, Chaturvedi TP, Gautam A, Singh A. Pyogenic Granuloma-Hyperplastic lesion of the gingiva: Case reports. The Open Dentistry Journal 2012;6:153-56.
4. Kamal R, Dahiya P, Puri A. Oral Pyogenic Granuloma: Various concepts of etiopathogenesis. J Oral Maxillofac Pathol 2012;16(1):79-82.
5. Jafarzadeh H, Sanatkhani M, Mohtasham N. Oral Pyogenic granuloma: A review. Journal of Oral Science .2006;48(4):167-75.
6. Gill S, Bali D, Uppal S. Pyogenic Granuloma- A case report. Research & Reviews: Journal of dental sciences 2016;4(3):124- 27.
7. Gondivkar SM, Gadbail A, Chole R. Oral Pregnancy Tumor. Contemporary Clinical Dentistry 2010;1(3):190-92.
8. Chattopadhyay S, Arora R, Agrawal S, Chatterjee S. Gummy tooth”: An Unusual Presentation of Pyogenic Granuloma. Annals of dental specialty 2013;01(01):27-29.
9. Mubeen K, Vijyalakshmi KR, Abhishek RP. Oral pyogenic granuloma with mandible involvement: an unusual presentation Dent Oral Hyg2011;3:6-9
10. Al-Mohaya MA, Al-Malik AM. Excision of oral pyogenic granuloma in a diabetic patient with 940nm diode laser. Saudi Med J 2016;37(12):1395-00.
11. Martins-Filho PRS, Piva MR, De Silva LCF, Reinheimer DM, Santos TS. Aggressive pregnancy tumor (pyogenic granuloma) with extensive alveolar bone loss mimicking a malignant tumor: case report and review of literature. Int J Morphol 2011; 29(1):164-67.
12. Kejriwal S, Bhandary R, Thomas B. Oral Pyogenic Granuloma: A Case Report 2014; 4(1):123-25.
13. Choukas NC, Toto PD. Pyogenic Granuloma: Report of a case. Oral Surg Oral Med Oral Pathol 1966;22:194-97.
14. Rai S, Kaur M, Bhatnagar P. Laser: A powerful tool for treatment of pyogenic granuloma. J Cutan Aesthet Surg 2011;4:144-47.
15. Asnaashari M, Mehdipour M, Moradi Abbas abadi F, Azari Marhabi S. Expedited removal of pyogenic granuloma by diode laser in a pediatric patient. J Laers Med Sci 2015;6:40-44.
16. Iyer VH, Sasikumar R. Management of oral pyogenic granuloma with 940nm diode laser; a rare case report. International Journal of laser dentistry 2013;3:100-04.
17. Azma E, Safavi N. Diode laser application in soft tissue Oral Surgery. Med Sci 2013;4:206-11.